

ORIGINAL ARTICLE

Patent Foramen Ovale and Cryptogenic Stroke in Older Patients

Michael Handke, M.D., Andreas Harloff, M.D., Manfred Olschewski, M.Sc.,
Andreas Hetzel, M.D., and Annette Geibel, M.D.

ABSTRACT

BACKGROUND

From the Departments of Cardiology and Angiology (M.H., A.G.), Neurology and Neurophysiology (A. Harloff, A. Hetzel), and Medical Biometry and Statistics (M.O.), University Hospital Freiburg, Freiburg, Germany. Address reprint requests to Dr. Handke at the Department of Cardiology, University Hospital Basel, Petersgraben 4, 4031 Basel, Switzerland, or at handkem@uhbs.ch.

Drs. Handke and Harloff contributed equally to this article.

N Engl J Med 2007;357:2262-8.
Copyright © 2007 Massachusetts Medical Society.

Studies to date have shown an association between the presence of patent foramen ovale and cryptogenic stroke in patients younger than 55 years of age. This association has not been established in patients 55 years of age or older.

METHODS

We prospectively examined 503 consecutive patients who had had a stroke, and we compared the 227 patients with cryptogenic stroke and the 276 control patients with stroke of known cause. We examined the prevalences of patent foramen ovale and of patent foramen ovale with concomitant atrial septal aneurysm in all patients, using transesophageal echocardiography. We also compared data for the 131 younger patients (<55 years of age) and those for the 372 older patients (≥55 years of age).

RESULTS

The prevalence of patent foramen ovale was significantly greater among patients with cryptogenic stroke than among those with stroke of known cause, for both younger patients (43.9% vs. 14.3%; odds ratio, 4.70; 95% confidence interval [CI], 1.89 to 11.68; $P<0.001$) and older patients (28.3% vs. 11.9%; odds ratio, 2.92; 95% CI, 1.70 to 5.01; $P<0.001$). Even stronger was the association between the presence of patent foramen ovale with concomitant atrial septal aneurysm and cryptogenic stroke, as compared with stroke of known cause, among both younger patients (13.4% vs. 2.0%; odds ratio, 7.36; 95% CI, 1.01 to 326.60; $P=0.049$) and older patients (15.2% vs. 4.4%; odds ratio, 3.88; 95% CI, 1.78 to 8.46; $P<0.001$). Multivariate analysis adjusted for age, plaque thickness, and presence or absence of coronary artery disease and hypertension showed that the presence of patent foramen ovale was independently associated with cryptogenic stroke in both the younger group (odds ratio, 3.70; 95% CI, 1.42 to 9.65; $P=0.008$) and the older group (odds ratio, 3.00; 95% CI, 1.73 to 5.23; $P<0.001$).

CONCLUSIONS

There is an association between the presence of patent foramen ovale and cryptogenic stroke in both older patients and younger patients. These data suggest that paradoxical embolism is a cause of stroke in both age groups.

THE CAUSE OF STROKE REMAINS UNIDENTIFIED by routine diagnostic testing in about 40% of patients.¹ One potential cause of embolic stroke is a patent foramen ovale, which enables right-to-left intracardiac shunting. The foramen ovale remains open in about one fourth of the general population. The prevalence decreases gradually with increasing age, from 34% during the first three decades to 20% during the ninth decade.²

An association between the presence of patent foramen ovale and cryptogenic stroke has been reported; however, the study populations consisted primarily of younger patients.³⁻⁶ Only a few studies have included older patients.⁷⁻⁹ A meta-analysis showed that the presence of patent foramen ovale in patients younger than 55 years of age is significantly associated with cryptogenic stroke, but the relationship has remained unconfirmed in patients 55 years of age or older.¹⁰ Proof of a significant relationship would have implications for diagnostic and therapeutic management.

The objectives of our study were to clarify whether there is a significant association between the presence of patent foramen ovale and cryptogenic stroke in patients 55 years of age or older and to compare the findings with those for younger patients. Our study population included all consecutive patients 18 to 85 years of age who were admitted to our stroke unit or our neurologic intensive care unit. We examined all patients for the presence or absence of patent foramen ovale, using transesophageal echocardiography.

METHODS

STUDY POPULATION

A total of 596 consecutive patients admitted to our stroke unit or neurologic intensive care unit fulfilled the inclusion criteria of an age of 18 to 85 years and the presence of suspected acute brain ischemia. These patients were enrolled in the study during the 16-month period between January 2001 and April 2002. Written informed consent was obtained from each patient or, if the patient was incapable of providing consent, from the patient's relatives. The study was approved by the local ethics committee.

Thirty-seven patients were excluded from analyses because transesophageal echocardiography could not be performed: 10 were too ill to undergo the procedure, 10 were transferred to an-

other clinic or died before the procedure could be performed, 14 had an uncontrollable gag reflex or gastrointestinal tract obstruction that precluded our performing the procedure, and 3 had undergone the procedure in another clinic but the method of data acquisition was inconsistent with our protocol. An additional 24 patients declined transesophageal echocardiography. Another 32 patients were excluded from analyses because their diagnosis on discharge was other than brain ischemia. Our analyses focused on the remaining 503 patients.

The following routine diagnostic tests were performed in all patients: cranial computed tomography, magnetic resonance imaging (MRI) of the brain, or both; and duplex sonography of the extracranial and intracranial arteries with a 4- to 7-MHz linear-array scanner (model ATL HDI 5000/3500, Advanced Technology Laboratories). The degree of stenosis of the internal carotid artery was defined according to the European Carotid Surgery Trial protocol.¹¹ Angiographic imaging of the intracranial and vertebrobasilar arteries was performed in 231 patients (45.9%), by means of time-of-flight angiography in patients who underwent MRI or by means of digital subtraction angiography before intraarterial thrombolysis therapy in the remaining patients. Angiography was not performed in 272 patients (54.1%). All patients underwent transthoracic echocardiography and electrocardiography. In patients with suspected paroxysmal atrial fibrillation (those with palpitations or a history of atrial fibrillation) or ambiguous results of routine diagnostic tests, we also performed 24-hour Holter monitoring.

Before transesophageal echocardiography was performed, we classified the cause of infarction according to the modified Trial of Org 10172 in Acute Stroke Treatment (TOAST) criteria.¹² The classification was done in advance to make possible a comparison of our data and those from earlier studies of the role of patent foramen ovale in stroke.¹⁰ The TOAST classification subdivides the cause of stroke into five subtypes, on the basis of clinical features and the results of diagnostic tests: large-artery atherosclerosis, cardioembolism, small-vessel occlusion, stroke of other known cause, and stroke of unknown cause. The patients with stroke whose cause was classified as one of the four known-cause subtypes were assigned to the known-cause group in our study. We deviated from the original TOAST criteria by assigning patients with two or more causes of

stroke to the known-cause group. Patients with stroke of causes that were unknown despite extensive routine diagnostic testing before transesophageal echocardiography were assigned to our cryptogenic-stroke group.

ECHOCARDIOGRAPHIC EXAMINATIONS

An ultrasonography system (ATL HDI 3500) was used for transthoracic examinations (with a 2-MHz transducer) and transesophageal examinations (with a 5-MHz transducer). Routine transthoracic echocardiography of the heart was performed in each patient. Within a median of 2 days after stroke onset (mean \pm SD, 3 \pm 2), all patients underwent transesophageal echocardiography. A contrast agent (oxypolygelatin [Gelifundol, Biotest]) was injected while the patient was at rest and while a Valsalva maneuver was performed. Patent foramen ovale was diagnosed when microbubbles were detected in the left atrium within four cycles after right-atrial opacification. Atrial septal aneurysm was diagnosed when the excursion of an abnormally redundant and mobile atrial septum was over 10 mm.¹³ The ascending aorta and the aortic arch, including the outlet of the left subclavian artery, were examined for aortic plaques. The thickest plaque was considered for classification.¹⁴

STATISTICAL ANALYSIS

Data are presented as means \pm SD for continuous variables and as absolute numbers and relative percentages for categorical variables. Group comparisons were performed by means of the Wil-

coxon rank-sum test for continuous variables and Fisher's exact test for categorical variables. Univariate and multivariate logistic-regression analyses were used to estimate the unadjusted and adjusted odds ratios and the corresponding 95% confidence intervals. The characteristics that affected the univariate analysis were included in the multivariable models: age, plaque thickness, presence or absence of coronary artery disease, and presence or absence of hypertension. All statistical tests were two-sided, and P values of less than 0.05 were considered to indicate statistical significance. All analyses were performed with the SAS statistical package (version 8.2).

RESULTS

BASILINE CHARACTERISTICS

The overall age range of the patients was 20 to 84 years (mean, 62.2 \pm 13.1). Of the 503 patients, 131 (26.0%) were younger than 55 years of age (mean, 45.3 \pm 8.3), and 372 (74.0%) were 55 years of age or older (mean, 68.0 \pm 7.0). The cause of stroke could be identified by means of routine diagnostic testing in 276 patients (54.9%). The stroke was classified as cryptogenic in the remaining 227 patients (45.1%), including 82 of the 131 patients younger than 55 years of age (62.6%) and 145 of the 372 patients 55 years of age or older (39.0%). As compared with the patients with stroke of known cause, the patients with cryptogenic stroke were on average 6 years younger and more of them had patent foramen ovale with or without a concomitant atrial septal aneurysm (Table 1). On the

Table 1. Baseline Characteristics of Patients with Cryptogenic Stroke or with Stroke of Known Cause.*

Characteristic	Cryptogenic Stroke (N=227)	Stroke of Known Cause (N=276)	P Value
Age — yr	58.2 \pm 13.9	64.5 \pm 10.4	<0.001
Female sex — no. (%)	94 (41.4)	97 (35.1)	0.17
PFO — no. (%)	77 (33.9)	34 (12.3)	<0.001
PFO-ASA — no. (%)	33 (14.5)	11 (4.0)	<0.001
Hypertension — no. (%)	143 (63.0)	222 (80.4)	<0.001
Diabetes — no. (%)	48 (21.1)	74 (26.8)	0.15
Hyperlipidemia — no. (%)	81 (35.7)	111 (40.2)	0.31
History of smoking — no. (%)	68 (30.0)	76 (27.5)	0.55
Coronary artery disease — no. (%)	41 (18.1)	82 (29.7)	0.003
Peripheral artery disease — no. (%)	12 (5.3)	20 (7.2)	0.46
Aortic plaque — mm	2.72 \pm 1.83	3.06 \pm 1.55	<0.001

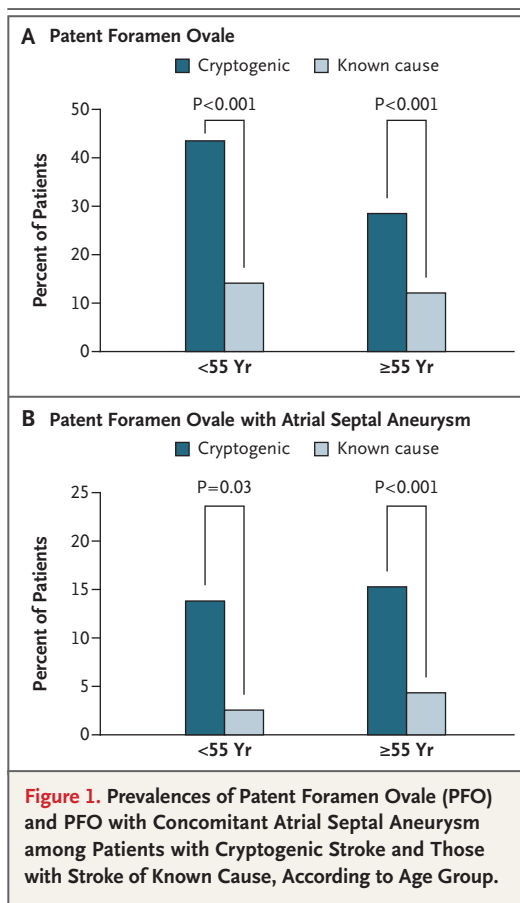
* Plus-minus values are means \pm SD. PFO denotes patent foramen ovale, and ASA atrial septum aneurysm.

other hand, patients with cryptogenic stroke had a lower prevalence of coronary artery disease or hypertension and slightly thinner aortic plaques than patients with stroke of known cause. There were no significant differences between the two groups with regard to sex or the presence or absence of diabetes, hyperlipidemia, history of smoking, or peripheral artery disease.

ASSOCIATION BETWEEN PATENT FORAMEN OVALE AND CRYPTOGENIC STROKE

The prevalence of patent foramen ovale was significantly greater among patients with cryptogenic stroke than among patients with stroke of known cause. This held true both for patients younger than 55 years of age (43.9% vs. 14.3%, $P<0.001$) and for patients 55 years of age or older (28.3% vs. 11.9%, $P<0.001$) (Fig. 1A). The prevalence of patent foramen ovale with concomitant atrial septal aneurysm was also greater among patients with cryptogenic stroke than among those with stroke of known cause, both in the younger group (13.4% vs. 2.0%, $P=0.03$) and in the older group (15.2% vs. 4.4%, $P<0.001$) (Fig. 1B). In the unadjusted univariate analysis, the odds ratios for patients younger than 55 years of age with cryptogenic stroke, as compared with stroke of known cause, were 4.70 (95% confidence interval [CI], 1.89 to 11.68; $P<0.001$) for the presence of patent foramen ovale and 7.36 (95% CI, 1.01 to 326.60; $P=0.049$) for the presence of patent foramen ovale with concomitant atrial septal aneurysm. Among patients 55 years of age or older, the odds ratios were smaller: 2.92 (95% CI, 1.70 to 5.01; $P<0.001$) for the presence of patent foramen ovale and 3.88 (95% CI, 1.78 to 8.46; $P<0.001$) for the presence of patent foramen ovale with concomitant atrial septal aneurysm. In the multivariate analysis, the presence of patent foramen ovale was independently associated with cryptogenic stroke (Fig. 2), both in the overall study population and in the younger and older groups. In contrast to the unadjusted odds ratios from the univariate analysis, the adjusted odds ratios from the multivariate analysis showed only a slight difference in the prevalence of patent foramen ovale among patients with cryptogenic stroke, as compared with stroke of known cause, in the younger group (odds ratio, 3.70; $P=0.008$) and the older group (odds ratio, 3.00; $P<0.001$).

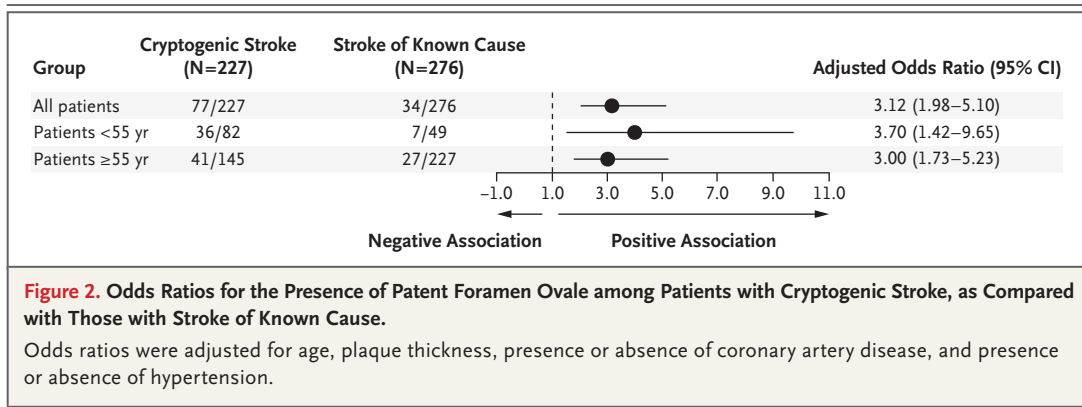
Among patients 55 years of age or older with cryptogenic stroke, atherosclerotic plaque thickness was significantly less in patients with patent



foramen ovale (2.78 ± 1.56 mm) and in those with patent foramen ovale with concomitant atrial septal aneurysm (2.64 ± 1.36 mm) than in patients without patent foramen ovale (3.65 ± 1.95 mm) (Fig. 3). These three subgroups did not differ significantly with respect to mean age (67.8 ± 8.0 years, 68.6 ± 8.0 years, and 67.9 ± 7.0 years, respectively; $P=0.81$). Among patients 55 years of age or older, the multivariate analysis also showed a nearly significant relationship between the thickness of the aortic plaque and the risk of cryptogenic stroke (odds ratio for patients with cryptogenic stroke vs. stroke of known cause, 1.15 per 1-mm increase in plaque thickness; 95% CI, 1.00 to 1.31; $P=0.05$).

DISCUSSION

We found an association between the presence of patent foramen ovale and cryptogenic stroke, not only in patients younger than 55 years of age but also in those 55 years of age or older. The relationship between the presence of patent foramen ovale and cryptogenic stroke was even more pro-



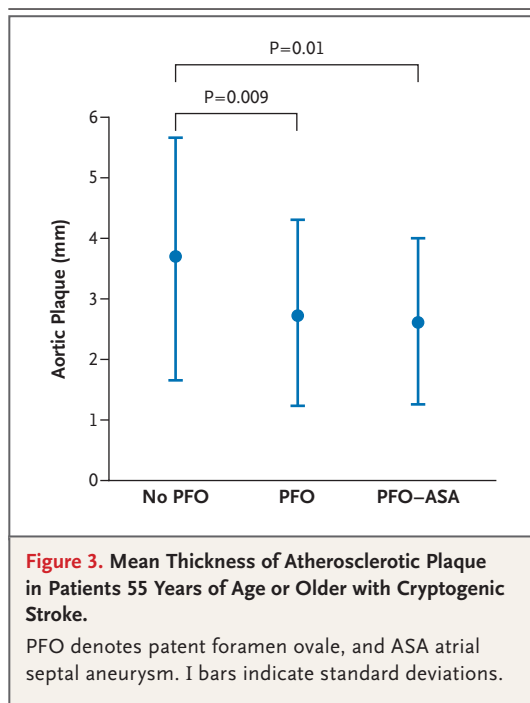
nounced among patients who had concomitant atrial septal aneurysm. Moreover, multivariate analysis showed that the presence of a patent foramen ovale was independently associated with cryptogenic stroke in both age groups.

Previous studies have been limited by selection bias, with older patients undergoing transesophageal echocardiography less often than younger patients.¹⁰ In our study, transesophageal echocardiography was performed for all patients. The prevalence of cryptogenic stroke in our study was relatively high, at 45%. However, we classified the cause of stroke before transesophageal echocardiography was performed, as was done in a recently published study.¹⁵ Two studies that reported prevalences of cryptogenic stroke lower than those in our study used available data from transesophageal echocardiography to classify the cause of stroke.^{16,17} We may have slightly overestimated the prevalence of cryptogenic stroke, because magnetic resonance angiography or digital subtraction angiography was performed in only about half the patients. As a result, some patients with intracranial large-artery atherosclerosis may have been erroneously assigned to the cryptogenic-stroke group.

It has long been debated whether the presence of patent foramen ovale actually does play a causal role in stroke or whether there is only a non-causal statistical relationship. However, there is considerable evidence¹⁸ that a patent foramen ovale can cause ischemic stroke, by means of paradoxical embolism. A positive relationship has been shown between the size of the shunt and the risk of stroke,¹⁹ patients with a residual shunt after occlusion of the patent foramen ovale have an increased rate of recurrence of stroke,²⁰ the rate of stroke is increased among patients with pulmonary embolism and a patent foramen ovale,²¹

and the migration of a thrombus through the patent foramen ovale can be directly visualized repeatedly,²² even in very elderly patients.^{23,24} The relationship is still controversial with respect to older patients,²⁵ because the available data are contradictory and are based on studies that used different diagnostic tests.⁷⁻⁹ In a study involving transthoracic echocardiography, Di Tullio et al. reported an increased prevalence of patent foramen ovale in all age groups with cryptogenic stroke.⁷ In one study using transesophageal echocardiography, and another using transcranial Doppler ultrasonography, for detection of right-to-left shunting after administration of contrast agent, there were no significant associations between the presence of patent foramen ovale and cryptogenic stroke.^{8,9} Data from these studies were insufficient to draw a conclusion for older patients with cryptogenic stroke.¹⁰

In addition to the significant association found in our study, additional considerations provide support for the hypothesis that patent foramen ovale plays a role in stroke in older patients. With increasing age, there is an increasing potential for paradoxical embolism,²⁶ since the incidence of venous thromboembolism increases exponentially with increasing age.²⁷ The combination of more frequent formation of thromboembolic material and hemodynamic changes promoting right-to-left shunting could contribute to an increased probability of paradoxical embolism in older patients.²⁸ A recent retrospective analysis showed that the presence of patent foramen ovale increases the risk of adverse events in older patients with cryptogenic stroke who are receiving aspirin or warfarin, but not in younger patients.²⁸ In addition, the diameter of the patent foramen ovale increases with age,² and this could make older patients more susceptible to paradoxical embolism.⁷



The question of causality between the presence of patent foramen ovale and stroke is, however, more difficult to answer with regard to older patients than with regard to younger patients, since older patients frequently have additional potential sources of emboli, such as atherosclerosis of the aorta.²⁹ This lends particular importance to the observation in our study that older patients with cryptogenic stroke and patent foramen ovale had significantly less severe atherosclerosis of the aortic arch than did patients without patent foramen ovale. The probability that the ischemia in the subgroup with patent foramen ovale is due to embolism from the aortic arch is correspondingly smaller, since the risk of embolism correlates with plaque thickness.²⁹

Consistent with other reports, our study showed a lower prevalence of patent foramen ovale in older patients with cryptogenic stroke than in younger patients.¹⁵ In addition to the fact that alternative causes should be taken into account

in older patients, it should be considered that the prevalence of patent foramen ovale decreases linearly with increasing age.² On the other hand, the numbers of patients with patent foramen ovale and concomitant atrial septal aneurysm who were younger than 55 years of age and who were 55 years of age or older were similar in both the cryptogenic-stroke group (13.4% and 15.2%, respectively) and the known-cause group (2.0% and 4.4%, respectively). Di Tullio et al. reported a low prevalence of patent foramen ovale with concomitant atrial septal aneurysm (1.7%) in the general population.³⁰ In a study of patients 55 years of age or younger, Mas et al. found that the presence of patent foramen ovale with concomitant atrial septal aneurysm is associated with a high risk of paradoxical embolism.¹³ Our data suggest that the presence of patent foramen ovale with concomitant atrial septal aneurysm is a high-risk characteristic in older patients as well.

In summary, our results show an association between the presence of patent foramen ovale and cryptogenic stroke in both patients younger than 55 years of age and those 55 years of age or older. There are no clear guidelines based on randomized trials for therapy if patent foramen ovale is present. There are several ongoing randomized studies (Randomized Evaluation of Recurrent Stroke Comparing PFO Closure to Established Current Standard of Care Treatment [RESPECT] trial, Evaluation of the STARFlex Septal Closure System in Patients with a Stroke or TIA due to the Possible Passage of Clot of Unknown Origin through a Patent Foramen Ovale [CLOSURE-1], and PC [Percutaneous Closure]-Trial: Patent Foramen Ovale and Cryptogenic Embolism); their results may clarify the effectiveness of percutaneous closure as compared with medical therapy. However, the patients in all three trials are 60 years of age or younger on enrollment, and studies that include older patients are needed to develop diagnostic and therapeutic management strategies for this large group of patients.

No potential conflict of interest relevant to this article was reported.

REFERENCES

1. Sacco RL, Ellenberg JH, Mohr JP, et al. Infarcts of undetermined cause: the NINCDS Stroke Data Bank. *Ann Neurol* 1989;25:382-90.
2. Hagen PT, Scholz DG, Edwards WD. Incidence and size of patent foramen ovale during the first 10 decades of life: an autopsy study of 965 normal hearts. *Mayo Clin Proc* 1984;59:17-20.
3. Lechat P, Mas JL, Lascault G, et al. Prevalence of patent foramen ovale in patients with stroke. *N Engl J Med* 1988;318:1148-52.
4. Webster MW, Chancellor AM, Smith HJ, et al. Patent foramen ovale in young stroke patients. *Lancet* 1988;2:11-2.
5. Cabanes L, Mas JL, Cohen A, et al. Atrial septal aneurysm and patent foramen ovale as risk factors for cryptogenic stroke in patients less than 55 years of age: a study using transesophageal

- echocardiography. *Stroke* 1993;24:1865-73.
6. Job FP, Ringelstein EB, Grafen Y, et al. Comparison of transcranial contrast Doppler sonography and transesophageal contrast echocardiography for the detection of patent foramen ovale in young stroke patients. *Am J Cardiol* 1994;74:381-4.
 7. Di Tullio M, Sacco RL, Gopal A, Mohr JP, Homma S. Patent foramen ovale as a risk factor for cryptogenic stroke. *Ann Intern Med* 1992;117:461-5.
 8. Jones EF, Calafiore P, Donnan GA, Tonkin AM. Evidence that patent foramen ovale is not a risk factor for cerebral ischemia in the elderly. *Am J Cardiol* 1994;74:596-9.
 9. Yeung M, Khan KA, Shuaib A. Transcranial Doppler ultrasonography in the detection of venous to arterial shunting in acute stroke and transient ischaemic attacks. *J Neurol Neurosurg Psychiatry* 1996;61:445-9.
 10. Overell JR, Bone I, Lees KR. Interatrial septal abnormalities and stroke: a meta-analysis of case-control studies. *Neurology* 2000;55:1172-9.
 11. MRC European Carotid Surgery Trialists' Collaborative Group. MRC European Carotid Surgery Trial: interim results for symptomatic patients with severe (70-99%) or with mild (0-29%) carotid stenosis. *Lancet* 1991;337:1235-43.
 12. Adams HP Jr, Bendixen BH, Kappelle LJ, et al. Classification of subtype of acute ischemic stroke: definitions for use in a multicenter clinical trial. *Stroke* 1993;24:35-41.
 13. Mas JL, Arquizan C, Lamy C, et al. Recurrent cerebrovascular events associated with patent foramen ovale, atrial septal aneurysm, or both. *N Engl J Med* 2001;345:1740-6.
 14. The French Study of Aortic Plaques in Stroke Group. Atherosclerotic disease of the aortic arch as a risk factor for recurrent ischemic stroke. *N Engl J Med* 1996;334:1216-21.
 15. De Castro S, Rasura M, Di Angelantonio E, et al. Distribution of potential sources of embolism in young and older stroke patients: implications for recurrent vascular events. *J Cardiovasc Med (Hagerstown)* 2006;7:191-6.
 16. Petty GW, Brown RD Jr, Whisnant JP, Sicks JD, O'Fallon WM, Wiebers DO. Ischemic stroke subtypes: a population-based study of incidence and risk factors. *Stroke* 1999;30:2513-6.
 17. Kolominsky-Rabas PL, Weber M, Gefeller O, Neundoerfer B, Heuschmann PU. Epidemiology of ischemic stroke subtypes according to TOAST criteria: incidence, recurrence, and long-term survival in ischemic stroke subtypes: a population-based study. *Stroke* 2001;32:2735-40.
 18. Windecker S, Wahl A, Nedeltchev K, et al. Comparison of medical treatment with percutaneous closure of patent foramen ovale in patients with cryptogenic stroke. *J Am Coll Cardiol* 2004;44:750-8.
 19. Stone DA, Godard J, Corretti MC, et al. Patent foramen ovale: association between the degree of shunt by contrast transesophageal echocardiography and the risk of future ischemic neurological events. *Am Heart J* 1996;131:158-61.
 20. Wahl A, Meier B, Haxel B, et al. Prognosis after percutaneous closure of patent foramen ovale for paradoxical embolism. *Neurology* 2001;57:1330-2.
 21. Kasper W, Geibel A, Tiede N, Just H. Patent foramen ovale in patients with haemodynamically significant pulmonary embolism. *Lancet* 1992;340:561-4.
 22. Kessel-Schaefer A, Lefkowitz M, Zellweger MJ, et al. Migrating thrombus trapped in a patent foramen ovale. *Circulation* 2001;103:1928.
 23. Iwanaga T, Iguchi Y, Shibazaki K, Inoue T, Kimura K. Paradoxical brain embolism in an acute stroke. *J Neurol Sci* 2007;254:102-4.
 24. Fraticelli A, Gambini C, Iannoni E, Paciaroni E. Impending paradoxical embolism through a patent foramen ovale in an octogenarian with pulmonary embolism: detection by transesophageal echocardiography and successful treatment by anticoagulation. *Arch Gerontol Geriatr* 1998;27:41-7.
 25. Nomura E, Matsumoto M. Cerebral infarction and patent foramen ovale (PFO) in the elderly: is PFO the culprit or not? *Intern Med* 2005;44:401-2.
 26. Meier B. Patent foramen ovale, guilty but only as a gang member and for a lesser crime. *J Am Coll Cardiol* 2006;47:446-8.
 27. Anderson FA Jr, Wheeler HB, Goldberg RJ, et al. A population-based perspective of the hospital incidence and case-fatality rates of deep vein thrombosis and pulmonary embolism: the Worcester DVT Study. *Arch Intern Med* 1991;151:933-8.
 28. Homma S, DiTullio MR, Sacco RL, Sciacca RR, Mohr JP. Age as a determinant of adverse events in medically treated cryptogenic stroke patients with patent foramen ovale. *Stroke* 2004;35:2145-9.
 29. Amarenco P, Cohen A, Tzourio C, et al. Atherosclerotic disease of the aortic arch and the risk of ischemic stroke. *N Engl J Med* 1994;331:1474-9.
 30. Di Tullio MR, Sacco RL, Sciacca RR, Jin Z, Homma S. Patent foramen ovale and the risk of ischemic stroke in a multiethnic population. *J Am Coll Cardiol* 2007;49:797-802.

Copyright © 2007 Massachusetts Medical Society.

RECEIVE IMMEDIATE NOTIFICATION WHEN
A JOURNAL ARTICLE IS RELEASED EARLY

To be notified when an article is released early on the Web and to receive the table of contents of the *Journal* by e-mail every Wednesday evening, sign up through our Web site at www.nejm.org