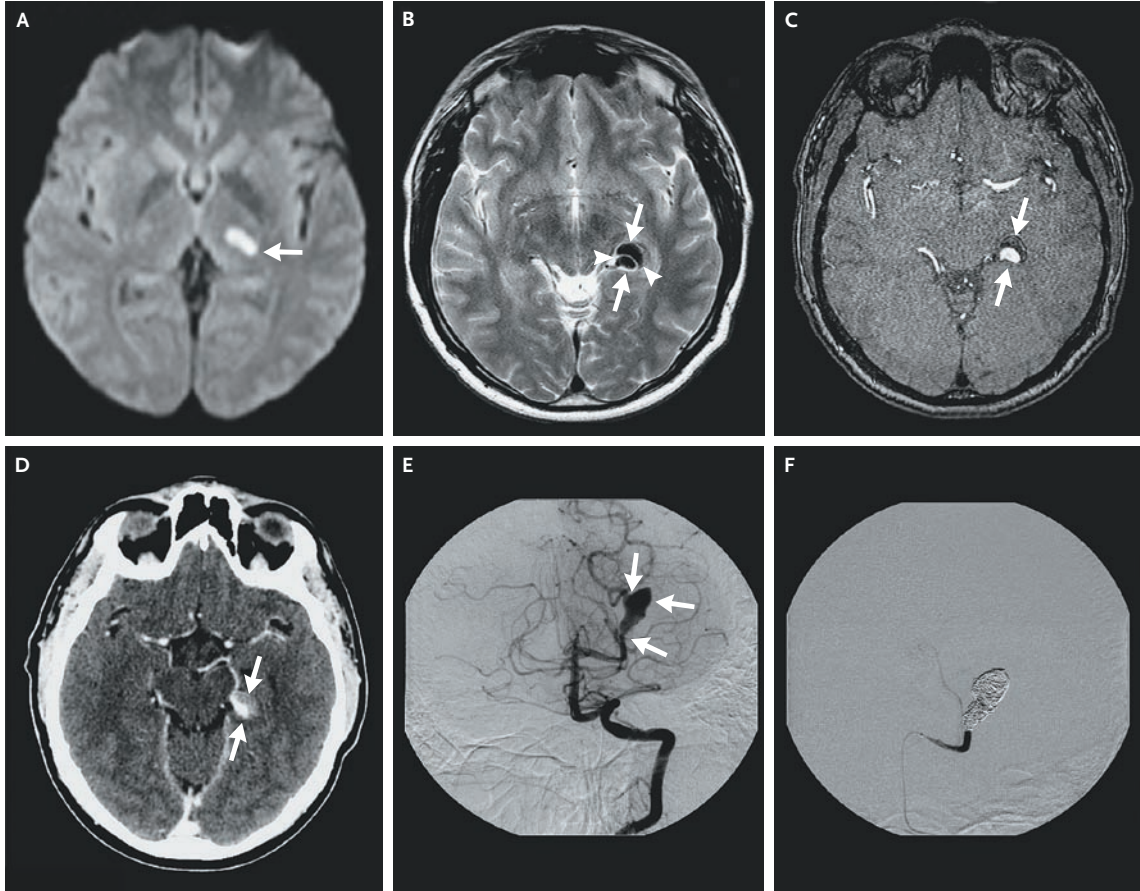


## IMAGES IN CLINICAL MEDICINE

## Dissecting Aneurysm of the Posterior Cerebral Artery



**A** 43-YEAR-OLD MAN PRESENTED WITH ACUTE-ONSET HEMIANESTHESIA INVOLVING THE RIGHT ARM, THE right leg, and the right side of the face. Six weeks earlier, he had a moderate occipital headache that lasted for 3 days. Diffusion-weighted magnetic resonance imaging (MRI) of the brain showed a thalamic lesion of restricted diffusion on the left side (Panel A, arrow), which was consistent with acute posterior choroidal-artery infarction. T<sub>2</sub>-weighted MRI scans, a magnetic resonance angiogram, and a computed tomographic angiogram (Panels B, C, and D, respectively) revealed a dilatation of the left posterior cerebral artery, with a double lumen — that is, a true circulating lumen (Panels B, C, and D, lower arrows) and a false noncirculating lumen (Panels B, C, and D, upper arrows), divided by an intimal flap (Panel B, arrowheads), suggesting a dissecting aneurysm. Angiography confirmed an aneurysm of the posterior cerebral artery (Panel E, arrows). The patient reported no specific risk factor (e.g., trauma) for arterial dissection. Uncomplicated occlusion of the aneurysm and the parent posterior cerebral artery was achieved with endovascular coils (Panel F). A few weeks later, progressive, painless paresthesias occurred in the right hemibody, which were unchanged at a 1-year follow-up visit. Dissecting intracranial aneurysms typically present with infarction (due to stenosis or embolism) or subarachnoid hemorrhage (due to rupture). Treatment options include conservative management, administration of antiplatelet agents, anticoagulation, and surgical or endovascular intervention. Therapeutic occlusion of the posterior cerebral artery distal to the perforating arteries to the thalamus and brain stem is often well tolerated because of collateral circulation.

Copyright © 2007 Massachusetts Medical Society.

Dimitri Renard, M.D.

Didier Milhaud, M.D.

Hôpital Gui de Chauliac, 34000 Montpellier, France, dimitrirenard@hotmail.com