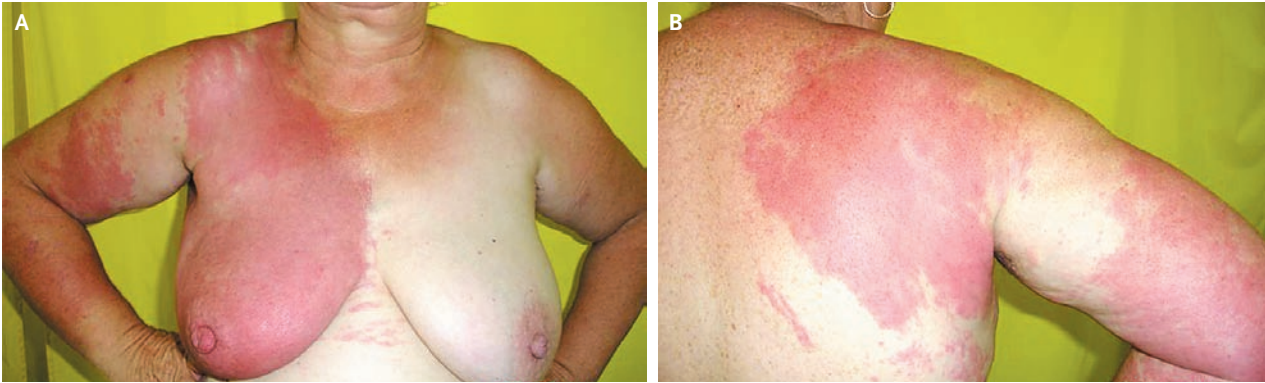


## IMAGES IN CLINICAL MEDICINE

## Cellulitis after Treatment for Breast Cancer



Gheorghe Peltecu, M.D., Ph.D.

Carol Davila University of Medicine  
010455 Bucharest, Romania  
peltecu@dnt.ro

A 54-YEAR-OLD WOMAN PRESENTED WITH A SUDDEN ONSET OF FEVER (temperature, 39.3°C) and erythema on the right breast and right arm (Panel A) and on the right side of the back (Panel B). There was no history of trauma. Eleven months earlier, she had undergone a wide local excision with axillary lymph-node dissection for an invasive ductal carcinoma (T2N0, 2.5 cm in diameter) of the ipsilateral breast. The postoperative course was uneventful, and she did not receive perioperative antibiotics. Surgery was followed by six courses of chemotherapy and 50 Gy of radiotherapy on the right breast. Examination of the breast revealed erythema, tenderness, and warmth, none of which crossed the midline, but no masses or lymphedema was palpable. The white-cell count was 13,300 per cubic millimeter. Ultrasonography showed no evidence of a soft-tissue abscess. The diagnosis of cellulitis was made, and the patient received oral antibiotics, with complete resolution of symptoms. A follow-up mammogram 6 weeks later showed no evidence of recurrent cancer.

Copyright © 2007 Massachusetts Medical Society.

## WEB-ONLY IMAGES IN CLINICAL MEDICINE

Click on "Featured Images" at [www.nejm.org](http://www.nejm.org) to see the *Journal's* Web-only Images in Clinical Medicine. The Images are listed (with e page numbers) in the table of contents of the printed *Journal* the week they are published and are compiled on the *Journal's* Web site.