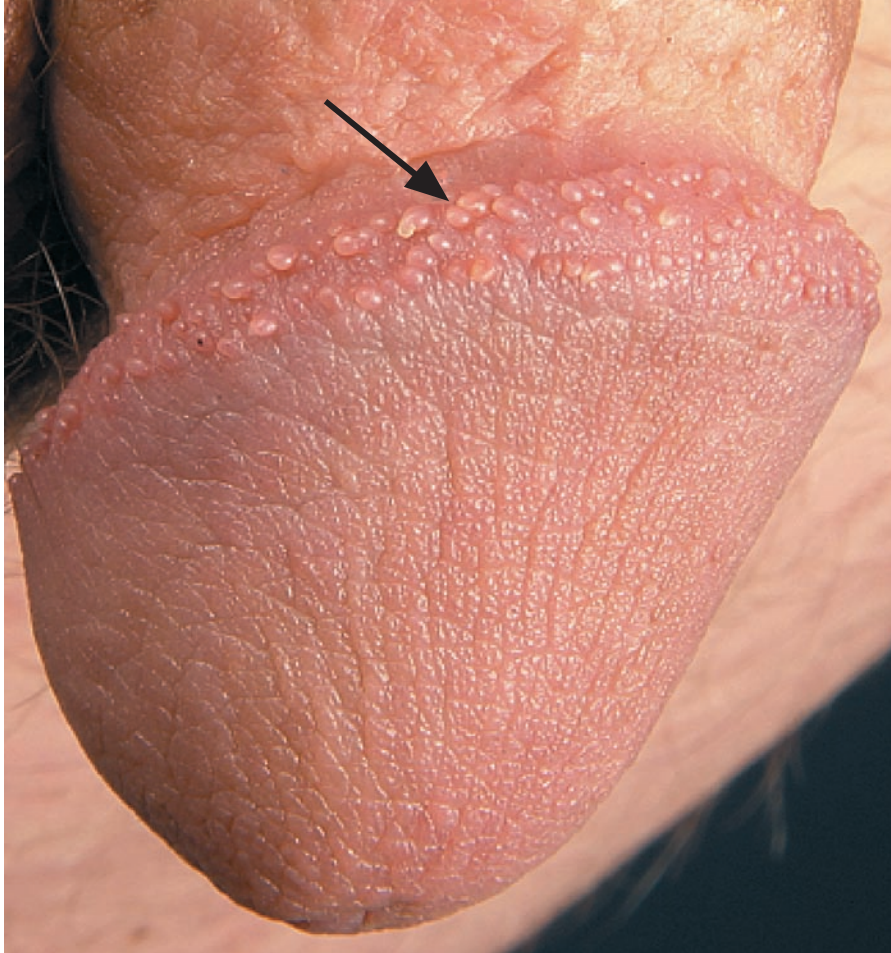


IMAGES IN CLINICAL MEDICINE

Pearly Penile Papules



A 19-YEAR-OLD MAN WAS REFERRED FOR TREATMENT OF MULTIPLE PAPULAR lesions that had appeared 8 years earlier on the glans of his circumcised penis and had been diagnosed as condyloma acuminatum. The lesions did not respond to treatment with various topical wart preparations. The patient reported no history of sexually transmitted infections and was anxious and embarrassed by the lesions. A genital examination revealed multiple tiny, smooth, skin-colored papules (arrow), distributed circumferentially along the coronal sulcus of the glans penis. Pearly penile papules are asymptomatic acral angiofibromas, typically distributed circumferentially on the corona and sulcus of the glans penis. They are more frequently found in men after puberty, with a reported incidence rate as high as 35%. This normal variant is seen more commonly in black and circumcised men. Familiarity with such anatomical variants, which may resemble various dermatoses, helps to relieve anxiety in patients and prevent unnecessary treatments.

Copyright © 2007 Massachusetts Medical Society.

Matilda Bylaite, M.D.
Thomas Ruzicka, M.D.

Ludwig-Maximilians University
of Munich
80337 Munich, Germany
matilda.bylaite@gmail.com