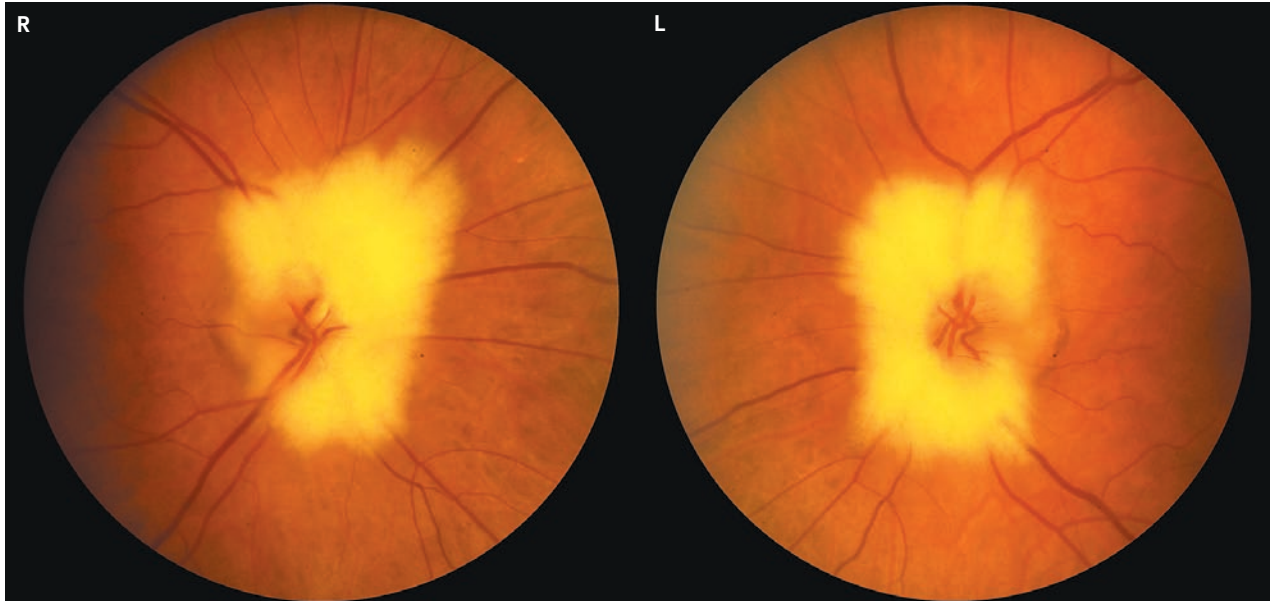


IMAGES IN CLINICAL MEDICINE

## Medical Mystery: Cloud Surrounding the Optic Disks



**A** 42-YEAR-OLD MAN PRESENTED FOR A ROUTINE EYE EXAMINATION. HIS best corrected visual acuity was 20/20 in both eyes, and examination of the anterior segment of each eye showed no abnormalities. Fundus photographs of both his eyes are shown. What is the most likely diagnosis?

Sandeep Randhawa, M.D.  
Andrew G. Lee, M.D.

University of Iowa Hospitals and Clinics  
Iowa City, IA 52242  
andrew-lee@uiowa.edu

*Editor's note:* We invite our readers to submit their answers at [www.nejm.org/mystery](http://www.nejm.org/mystery). We will publish the diagnosis in the Correspondence section of the February 28, 2008, issue and e-mail it to everyone who submits an answer. All answers must be received by January 16, 2008.

Copyright © 2008 Massachusetts Medical Society.