

BRIEF REPORT

Chimerism and Tolerance in a Recipient of a Deceased-Donor Liver Transplant

Stephen I. Alexander, M.B., B.S., Neil Smith, M.B., B.S., Min Hu, M.D., M.Med., Deborah Verran, M.B., Ch.B., Albert Shun, M.B., B.S., Stuart Dorney, M.B., B.S., Arabella Smith, M.B., B.S., Boyd Webster, M.B., Ch.B., Peter John Shaw, M.B., B.S., Ahti Lammi, M.B., B.S., and Michael O. Stormon, M.B., B.S.

SUMMARY

Complete hematopoietic chimerism and tolerance of a liver allograft from a deceased male donor developed in a 9-year-old girl, with no evidence of graft-versus-host disease 17 months after transplantation. The tolerance was preceded by a period of severe hemolysis, reflecting partial chimerism that was refractory to standard therapies. The hemolysis resolved after the gradual withdrawal of all immunosuppressive therapy.

CASE REPORT

Acute fulminant hepatitis after a nonspecific viral illness developed in a previously well 9-year-old girl. Her blood group was O, RhD-negative. She was referred to our institution, and at the time of admission she had markedly elevated aminotransferase levels and evidence of marked synthetic dysfunction (Table 1). Extensive testing ruled out known viral, metabolic, drug-related, and autoimmune causes, and a diagnosis of “non-A-to-G viral hepatitis” was made. A liver biopsy was not performed because of severe underlying coagulopathy.

Given the patient’s fulminant hepatic failure (Table 1) requiring mechanical ventilation, urgent liver transplantation was performed with the use of a whole-organ transplant from an O, RhD-positive 12-year-old male donor who was positive for cytomegalovirus (CMV) (the recipient was also CMV-positive) and who died of hypoxic brain injury. The whole liver was transplanted (cold ischemic time, 9 hours 46 minutes), and the biliary anastomosis was a choledochocholedochostomy. The HLA status of the donor was A34,68;B50,76;DR4,13, and the recipient’s HLA status was A2,24;B37,62;DR7,9.

Initial standard immunosuppressive therapy after liver transplantation consisted of tacrolimus (trough level, 12 to 15 μg per liter), intravenous methylprednisolone (2 mg per kilogram of body weight on days 0 through 2, 1.5 mg per kilogram on days 3 through 5, and then 1 mg per kilogram per day), and intravenous azathioprine (1.5 mg per kilogram per day). Other medications included intravenous ganciclovir for CMV prophylaxis (5 mg per kilogram per day) and antibiotic therapy. Antifungal prophylaxis was not administered.

On day 13 after transplantation, acute biliary obstruction developed, requiring operative choledochoduodenostomy and division of adhesions. Profound lymphopenia (lymphocyte count, 0.5×10^9 per liter), which had been noted at presentation, persisted for 25 weeks after transplantation; it was considered to be due to the

From the Centre for Kidney Research (S.I.A., M.H.); the Children’s Hospital at Westmead and the Department of Paediatrics and Child Health, University of Sydney (S.I.A., N.S., A. Shun, S.D., A. Smith, B.W., P.J.S., A.L., M.O.S.); and the Australian National Liver Transplant Unit (D.V., A. Shun, S.D., M.O.S.) — all in Sydney. Address reprint requests to Dr. Stormon at the Department of Gastroenterology, Children’s Hospital at Westmead, Locked Bag 4001, 2145, Sydney, Australia, or at michaes6@chw.edu.au.

N Engl J Med 2008;358:369-74.

Copyright © 2008 Massachusetts Medical Society.

Table 1. Results of Laboratory Tests before and after Liver Transplantation and after Discontinuation of Immunosuppressive Therapy.*

Variable	Reference Value†	On Admission	Before Transplantation	12 Mo after Transplantation	5 Yr after Transplantation
Aspartate aminotransferase (U/liter)	0–50	2363	1875	37	34
Alanine aminotransferase (U/liter)	0–50	2651	2357	49	25
Direct bilirubin (mg/dl)	0.0–0.2	15.9	18.6	3.1	0.1
Albumin (g/dl)	3.0–4.4	2.5	2.1	4.1	4.3
INR	1.0–1.2	5.3	7.9	1.0	1.0
Hemoglobin (g/liter)		129	82	40	130
White-cell count (10 ⁹ /liter)		4.6	5.6	22.8	8.5
Lymphocyte count (10 ⁹ /liter)		0.5	0.3	3.4	2.9
Ammonia (μg/dl)	5–10	133	265	NM	NM

* To convert the values for direct bilirubin to micromoles per liter, multiply by 17.1. To convert the values for ammonia to micromoles per liter, multiply by 0.5872. INR denotes international normalized ratio, and NM not measured.

† The reference values are used for children at the Children's Hospital at Westmead, Sydney.

precipitating viral agent and the immunosuppressive therapy. The patient was discharged 33 days after transplantation while receiving tacrolimus (trough level, 10 to 12 μg per liter) and prednisone (0.5 mg per kilogram per day). Azathioprine was discontinued 2 days after transplantation because of lymphopenia, and pneumocystis prophylaxis with cotrimoxazole was initiated.

Readmission was required 2 weeks after discharge, when a maculopapular exanthem, fever, and chest pain developed in the patient. Upper endoscopic examination and a biopsy specimen showed CMV esophagitis. The biopsy specimen showed viral inclusions and positive staining for CMV, and testing for CMV antigenemia was positive. The CMV esophagitis was successfully treated with a 2-week course of intravenous ganciclovir, which was then switched to oral valgacyclovir because of lymphopenia (lymphocyte count 0.1×10⁹ per liter), with a total white-cell count of 2.1×10⁹ per liter. Three months after transplantation, immunosuppressive therapy consisted of tacrolimus (trough level, 8 to 10 μg per liter) and prednisone at a dose of 2.5 mg daily, and treatment of CMV was continued with valgacyclovir. The lymphocyte count had improved (0.7×10⁹ per liter).

Nine months after transplantation, a small-bowel obstruction developed, requiring surgical division of adhesions and resection of an ileal band. Routine preoperative blood grouping revealed that the patient's blood group had changed from O, RhD-negative, to O, RhD-positive (the

donor's blood group), and a weakly positive direct antiglobulin test indicated coating of red blood cells with IgG antibodies. At that time, there was no evidence of spherocytosis on the blood film to suggest hemolysis; the hemoglobin level was 95 g per liter. This finding was confirmed by the Australian Red Cross Blood Service. Both parents had group O, RhD-negative blood with the phenotype ccdee, whereas their daughter's phenotype was now cDEe. However, serum samples showed mixed-field reactions with anti-D and anti-E typing.

Ten months after transplantation, after a mild upper respiratory tract infection, anemia (hemoglobin level, 64 g per liter) developed in the patient. Laboratory tests at that time showed active hemolysis, a strongly positive direct antiglobulin test result, and compensatory reticulocytosis (reticulocyte count, up to 29%). The indirect antiglobulin test and saline techniques showed high levels of active autoantibodies; the patient was treated with prednisone at doses of 5 mg per kilogram per day. Examination of a nasopharyngeal aspirate showed no respiratory viruses, and a serologic analysis to detect mycoplasma infection was negative. A transient improvement in the hemoglobin level was observed; however, as the prednisone was tapered, the anemia recurred. Severe intravascular hemolysis with hemoglobinuria and transient renal insufficiency developed. Multiple transfusions of group O, RhD-negative blood were required. The corticosteroid treatment resulted in severe cushingoid features; normal re-

sults of liver-function tests were maintained. Other therapies for treating the hemolysis included intravenous immune globulin and a switch from tacrolimus to cyclosporine.¹

The change in this patient from group O, RhD-negative blood to group O, RhD-positive blood suggested the development of chimerism by engraftment of the recipient marrow from passenger hematopoietic stem cells within the transplanted liver. Fluorescence in situ hybridization studies for the X and Y chromosomes were performed on a bone marrow aspirate and peripheral-blood lymphocytes 3 months after the onset of hemolysis (post-transplantation day 395).² Analysis of cells from the marrow, sorted by means of flow cytometry, showed that they were male (XY) in myeloid, erythroid, and CD19+ B cells. Analysis of peripheral-blood aliquots revealed a predominantly male (donor) population: of 50 T cells, 94% were male and 6% were female; of 50 B cells, 98% were male and 2% were female; of 50 granulocytes, 100% were male; and of 50 natural killer cells, 100% were male (Fig. 1). A total of 190 sorted peripheral-blood cells were further assessed on post-transplantation day 417, and 250 cells were assessed on post-transplantation day 492 (2 months after immunosuppressive therapy had been discontinued); all of these cells were male.

These results suggested that the hemolysis was due to the production of antibodies by residual B lymphocytes in the recipient against engrafted erythroid cells from the donor. A choice between two therapeutic options was then considered: the use of rituximab, an anti-CD20 monoclonal antibody, which would deplete all B cells (both host and donor cells), or withdrawal of all immunosuppressive therapy to allow full engraftment. The decision was made to withdraw the immunosuppressive therapy.

Fourteen months after transplantation (4 months after the onset of hemolytic anemia), cyclosporine was discontinued, and the prednisone dose was slowly tapered over a period of 3 months. The hemoglobin level remained stable without transfusions, and the reticulocyte count returned to normal, whereas the direct antiglobulin test remained weakly positive until 28 months later.

The patient remains well 5 years after transplantation. She has not received any immunosuppressive therapy for 4 years, and the results of her liver-function tests are normal. A repeat liver bi-

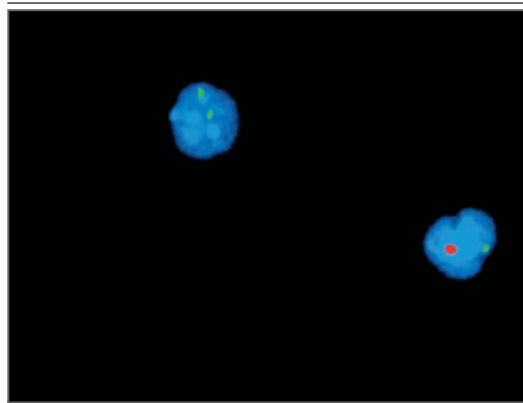


Figure 1. Fluorescence In Situ Hybridization for the X and Y Chromosomes on a Bone Marrow Aspirate Obtained from the Patient 12 Months after Transplantation.

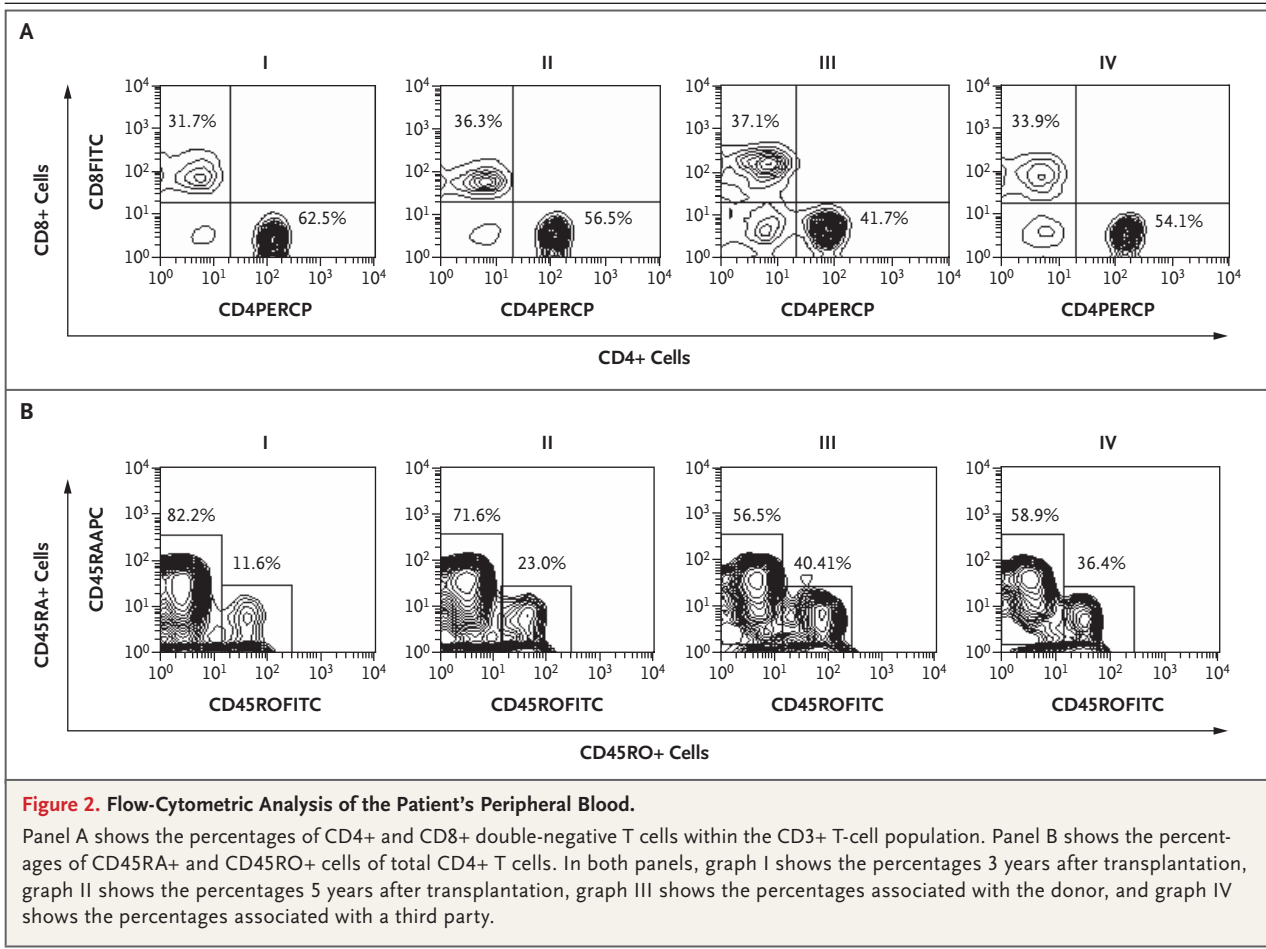
Signals were detected in interphase with the use of probes CEPX (Vysis), which hybridizes to the X centromere (green signal), and DYZ1 (red signal), which hybridizes to the Y heterochromatin.

opsy has not been performed because it has not been indicated clinically.

The patient has never had any dermatologic or gastrointestinal symptoms to suggest graft-versus-host disease. Repeat studies have shown conversion of her peripheral blood to the HLA of the donor: A34,68; B50,76; DR4,13. Furthermore, the loss of antibody responses to measles and mumps occurred after discontinuation of all immunosuppressive therapy despite normal antibody levels before transplantation, requiring immunization again with standard vaccines. Normal antibody responses to measles, mumps, and rubella were restored after revaccination.

The patient's lymphocyte T-cell subgroups CD4 and CD8, B cells, and natural killer cells are now normal. Analysis of her peripheral blood showed a predominantly naive, CD45RA-expressing CD4 population (Fig. 2A and 2B).

Assessment of the levels of T-cell-receptor excision circles, a marker of early T cells derived from the thymus, showed a high level in the recipient's peripheral blood, a finding suggestive of thymic engraftment rather than peripheral expansion of engrafting donor cells (Fig. 3). Finally, assessment of antidonor responses in the patient by means of mixed-lymphocyte culture 3 years after transplantation showed donor-specific unresponsiveness with normal third-party responses (Fig. 4).^{3,4}



DISCUSSION

Complete hematopoietic chimerism classically occurs in bone marrow transplantation, during which all bone marrow-derived cells in the recipient are eliminated and replaced by donor cells.⁵ Partial or mixed chimerism in bone marrow transplantation occurs when milder forms of preconditioning are used, which initially do not completely ablate the host hematopoietic system.⁵ Microchimerism, or donor T-cell chimerism, is common after liver transplantation, but it usually disappears within the first 3 weeks.⁶ The effect of microchimerism in recipients of solid-organ transplants is uncertain, with reported findings ranging from correlation with graft acceptance and tolerance⁷ to no influence on either tolerance^{5,8} or the prevention of rejection.^{9,10}

Severe hemolytic anemia 10 months after liver transplantation in this young girl was associated with mixed chimerism, and the initial studies

showed the marrow and the majority of lymphocytes to be of donor origin. Since the patient had become RhD-positive, and high levels of hemolytic antibodies were detected, the likely source was her own B cells. The loss of antibodies to common vaccines in this patient provides further support for this theory, but their reappearance after revaccination suggests a donor-derived, naive B-cell compartment.

This patient resembles children with cancer and T-cell-deficient patients who have received bone marrow transplants after nonmyeloablative therapy and have evidence of thymic engraftment, with the appearance of naive CD4 T cells and high levels of T-cell-receptor excision circles.^{11,12} This patient's course is also consistent with animal models of mixed chimerism in which engrafting donor cells move through the thymus and host-reactive cells are deleted. This phenomenon is also found in mouse models in which viral superantigens in the thymus are expressed, lead-

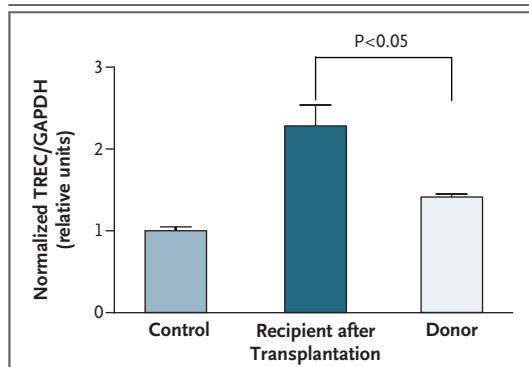


Figure 3. Analysis of T-Cell–Receptor Excision Circles.

DNA measurement of T-cell–receptor excision circles (TRECs) in peripheral blood was performed by means of a real-time polymerase-chain-reaction assay. The samples of peripheral-blood mononuclear cells were obtained from the donor and from the patient 5 years after transplantation. TREC levels are shown relative to the levels in a control sample of peripheral blood from an adult. GAPDH denotes glyceraldehyde-3-phosphate dehydrogenase.

ing to the deletion of cells expressing reactive T-cell receptor $V\beta$ s. Furthermore, central deletion of CD4 and CD8 alloreactive T-cell receptor transgenic T cells occurs within 4 weeks after mixed chimerism bone marrow transplantation, with no evidence of peripheral regulation.¹³⁻¹⁶

The achievement of central tolerance has been a major goal of transplantation research, but in clinical practice, it has been limited by the development of severe graft-versus-host disease and complications related to induction regimens. In a patient who had received an HLA-identical bone marrow transplant, subsequent successful liver transplantation from the same donor, with discontinuation of immunosuppressive therapy, was reported.¹⁷ The use of nonmyeloablative conditioning and stem-cell infusion, followed by receipt of a liver transplant from a living related donor, has also resulted in various levels of chimerism and tolerance after transplantation, although graft-versus-host disease usually precludes the withdrawal of immunosuppressive therapy.¹⁸ Graft-versus-host disease has also been reported to be a major complication of donor hematopoiesis occurring spontaneously after liver transplantation, resulting in either death of the patient¹⁸ or disease requiring ongoing immunosuppressive therapy.¹⁹⁻²¹ Furthermore, certain immune changes in peripheral blood may predispose liver-transplant recipients to “operational tolerance.”²²

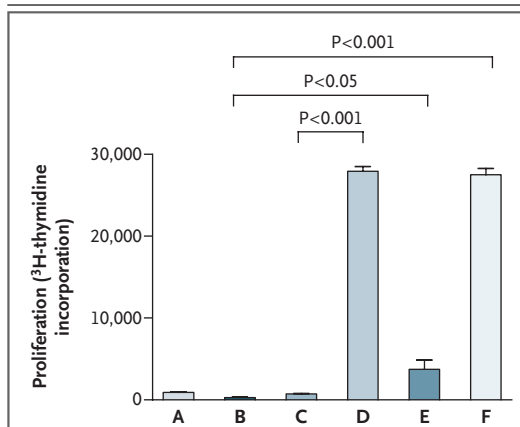


Figure 4. Mixed-Lymphocyte Culture of Peripheral-Blood Mononuclear Cells.

The mixed-lymphocyte culture 5 years after transplantation showed donor-specific unresponsiveness. A shows the patient's response to the patient; B shows the third-party response to itself; C shows the patient's response to the donor; D shows the patient's response to the third party; E shows the donor's response to the third party; and F shows the third party's response to the donor.

In this patient, the profound lymphopenia at presentation and in the subsequent months after transplantation, plus the immunosuppressive effects of drugs such as tacrolimus, azathioprine, and ganciclovir, may have contributed to the engraftment of donor hematopoietic stem cells. In addition, CMV infection, which resulted in clinically significant disease in the early period after transplantation, can have immune-modifying effects, which may have contributed to the eventual engraftment with donor cells.^{23,24} Finally, the numbers of stem cells from the liver may have been enhanced because of the relatively young age of the donor.

In summary, this patient required urgent liver transplantation for non-A-to-G hepatitis, and hemolytic anemia subsequently developed as a result of host-versus-graft disease, suggesting mixed hematopoietic chimerism. Withdrawal of immunosuppressive therapy resulted in resolution of the hemolytic anemia and the development of full hematologic chimerism. The complete absence of graft-versus-host disease and normal liver function in a fully HLA-mismatched, sex-mismatched liver allograft show that mixed chimerism with full tolerance can occur naturally under specific circumstances.

A Supplementary Appendix is available with the full text of this article at www.nejm.org.

Supported by a grant from the Juvenile Diabetes Research Foundation (4-2006-1025).

No potential conflict of interest relevant to this article was reported.

We thank Prof. Simon Robson for insightful suggestions and Dr. Geoff Zhang for his assistance.

REFERENCES

1. Abu-Elmagd KM, Bronsther O, Kobayashi M, et al. Acute hemolytic anemia in liver and bone marrow transplant patients under FK 506 therapy. *Transplant Proc* 1991;23:3190-2.
2. Starzl TE, Demetris AJ, Trucco M, et al. Systemic chimerism in human female recipients of male livers. *Lancet* 1992;340:876-7.
3. Kraus AB, Shaffer J, Toh HC, et al. Early host CD8 T-cell recovery and sensitized anti-donor interleukin-2-producing and cytolytic T-cell responses associated with marrow graft rejection following nonmyeloablative bone marrow transplantation. *Exp Hematol* 2003;31:609-21.
4. Ponchel F, Toomes C, Bransfield K, et al. Real-time PCR based on SYBR-Green I fluorescence: an alternative to the TaqMan assay for a relative quantification of gene rearrangements, gene amplifications and micro gene deletions. *BMC Biotechnol* 2003;3:18. (Accessed December 28, 2007, at <http://www.biomedcentral.com/1472-6750/3/18>.)
5. Wekerle T, Sykes M. Mixed chimerism as an approach for the induction of transplantation tolerance. *Transplantation* 1999;68:459-67.
6. Domiati-Saad R, Klintmalm GB, Netto G, Agura ED, Chinnakotla S, Smith DM. Acute graft versus host disease after liver transplantation: patterns of lymphocyte chimerism. *Am J Transplant* 2005;5:2968-73.
7. Starzl TE, Demetris AJ, Murase N, Ildstad S, Ricordi C, Trucco M. Cell migration, chimerism, and graft acceptance. *Lancet* 1992;339:1579-82.
8. Schlitt HJ. Is microchimerism needed for allograft tolerance? *Transplant Proc* 1997;29:82-4.
9. Sivasai KS, Alevy YG, Duffy BF, et al. Peripheral blood microchimerism in human liver and renal transplant recipients: rejection despite donor-specific chimerism. *Transplantation* 1997;64:427-32.
10. Schlitt HJ, Hundrieser J, Ringe B, Pichlmayr R. Donor-type microchimerism associated with graft rejection eight years after liver transplantation. *N Engl J Med* 1994;330:646-7.
11. Savage WJ, Bleesing JJ, Douek D, et al. Lymphocyte reconstitution following nonmyeloablative hematopoietic stem cell transplantation follows two patterns depending on age and donor/recipient chimerism. *Bone Marrow Transplant* 2001;28:463-71.
12. Cavazzana-Calvo M, Carlier F, Le Deist F, et al. Long-term T-cell reconstitution after hematopoietic stem-cell transplantation in primary T-cell-immunodeficient patients is associated with myeloid chimerism and possibly the primary disease phenotype. *Blood* 2007;109:4575-81.
13. Kurtz J, Shaffer J, Lie A, Anosova N, Benichou G, Sykes M. Mechanisms of early peripheral CD4 T-cell tolerance induction by anti-CD154 monoclonal antibody and allogeneic bone marrow transplantation: evidence for anergy and deletion but not regulatory cells. *Blood* 2004;103:4336-43.
14. Wekerle T, Kurtz J, Ito H, et al. Allogeneic bone marrow transplantation with co-stimulatory blockade induces macrochimerism and tolerance without cytoreductive host treatment. *Nat Med* 2000;6:464-9.
15. Manilay JO, Pearson DA, Sergio JJ, Swenson KG, Sykes M. Intrathymic deletion of alloreactive T cells in mixed bone marrow chimeras prepared with a nonmyeloablative conditioning regimen. *Transplantation* 1998;66:96-102.
16. Nikolic B, Sykes M. Bone marrow chimerism and transplantation tolerance. *Curr Opin Immunol* 1997;9:634-40.
17. Andreoni KA, Lin JI, Groben PA. Liver transplantation 27 years after bone marrow transplantation from the same living donor. *N Engl J Med* 2004;350:2624-5.
18. Donckier V, Troisi R, Toungouz M, et al. Donor stem cell infusion after nonmyeloablative conditioning for tolerance induction to HLA mismatched adult living-donor liver graft. *Transpl Immunol* 2004;13:139-46.
19. Collins RH Jr, Anastasi J, Terstappen LW, et al. Donor-derived long-term chimerism in a liver-transplant recipient. *N Engl J Med* 1993;328:762-5.
20. Whittington PF, Rubin CM, Alonso EM, et al. Complete lymphoid chimerism and chronic graft-versus-host disease in an infant recipient of a hepatic allograft from an HLA-homozygous parental living donor. *Transplantation* 1996;62:1516-9.
21. Gilroy RK, Coccia PF, Talmadge JE, et al. Donor immune reconstitution after liver-small bowel transplantation for multiple intestinal atresia with immunodeficiency. *Blood* 2004;103:1171-4.
22. Li Y, Koshiba T, Yoshizawa A, et al. Analyses of peripheral blood mononuclear cells in operational tolerance after pediatric living donor liver transplantation. *Am J Transplant* 2004;4:2118-25.
23. Mocarski ES Jr. Immune escape and exploitation strategies of cytomegaloviruses: impact on and imitation of the major histocompatibility system. *Cell Microbiol* 2004;6:707-17.
24. Wang EC, McSharry B, Retiere C, et al. UL40-mediated NK evasion during productive infection with human cytomegalovirus. *Proc Natl Acad Sci U S A* 2002;99:7570-5.

Copyright © 2008 Massachusetts Medical Society.

COLLECTIONS OF ARTICLES ON THE JOURNAL'S WEB SITE

The *Journal's* Web site (www.nejm.org) sorts published articles into more than 50 distinct clinical collections, which can be used as convenient entry points to clinical content. In each collection, articles are cited in reverse chronological order, with the most recent first.