

# The NEW ENGLAND JOURNAL of MEDICINE

ESTABLISHED IN 1812

FEBRUARY 7, 2008

VOL. 358 NO. 6

## Thrombus Aspiration during Primary Percutaneous Coronary Intervention

Tone Svilaas, M.D., Pieter J. Vlaar, M.Sc., Iwan C. van der Horst, M.D., Ph.D., Gilles F.H. Diercks, M.D., Ph.D.,  
Bart J.G.L. de Smet, M.D., Ph.D., Ad F.M. van den Heuvel, M.D., Ph.D., Rutger L. Anthonio, M.D., Ph.D.,  
Gillian A. Jessurun, M.D., Ph.D., Eng-Shiong Tan, M.D., Albert J.H. Suurmeijer, M.D., Ph.D.,  
and Felix Zijlstra, M.D., Ph.D.

### ABSTRACT

#### BACKGROUND

Primary percutaneous coronary intervention (PCI) is effective in opening the infarct-related artery in patients with myocardial infarction with ST-segment elevation. However, the embolization of atherothrombotic debris induces microvascular obstruction and diminishes myocardial reperfusion.

#### METHODS

We performed a randomized trial assessing whether manual aspiration was superior to conventional treatment during primary PCI. A total of 1071 patients were randomly assigned to the thrombus-aspiration group or the conventional-PCI group before undergoing coronary angiography. Aspiration was considered to be successful if there was histopathological evidence of atherothrombotic material. We assessed angiographic and electrocardiographic signs of myocardial reperfusion, as well as clinical outcome. The primary end point was a myocardial blush grade of 0 or 1 (defined as absent or minimal myocardial reperfusion, respectively).

#### RESULTS

A myocardial blush grade of 0 or 1 occurred in 17.1% of the patients in the thrombus-aspiration group and in 26.3% of those in the conventional-PCI group ( $P < 0.001$ ). Complete resolution of ST-segment elevation occurred in 56.6% and 44.2% of patients, respectively ( $P < 0.001$ ). The benefit did not show heterogeneity among the baseline levels of the prespecified covariates. At 30 days, the rate of death in patients with a myocardial blush grade of 0 or 1, 2, and 3 was 5.2%, 2.9%, and 1.0%, respectively ( $P = 0.003$ ), and the rate of adverse events was 14.1%, 8.8%, and 4.2%, respectively ( $P < 0.001$ ). Histopathological examination confirmed successful aspiration in 72.9% of patients.

#### CONCLUSIONS

Thrombus aspiration is applicable in a large majority of patients with myocardial infarction with ST-segment elevation, and it results in better reperfusion and clinical outcomes than conventional PCI, irrespective of clinical and angiographic characteristics at baseline. (Current Controlled Trials number, ISRCTN16716833.)

From the University Medical Center Groningen, University of Groningen, Groningen, the Netherlands. Address reprint requests to Dr. Svilaas at the Thorax Center, Department of Cardiology, Triadegebouw, Gang LM1.004, University Medical Center Groningen, University of Groningen, P.O. Box 30.001, 9700 RB Groningen, the Netherlands, or at [fzijlstra@thorax.umcg.nl](mailto:fzijlstra@thorax.umcg.nl).

N Engl J Med 2008;358:557-67.

Copyright © 2008 Massachusetts Medical Society.

**A**CUTE MYOCARDIAL INFARCTION WITH ST-segment elevation is caused by the rupture or erosion of an atherosclerotic plaque, initiating intraluminal thrombosis resulting in partial or complete occlusion of a coronary artery.<sup>1-3</sup> Primary percutaneous coronary intervention (PCI) is the preferred treatment for myocardial infarction with ST-segment elevation and is effective in opening the infarct-related artery.<sup>4-6</sup> However, microvascular obstruction with diminished myocardial perfusion occurs in a large proportion of patients with a patent epicardial vessel after primary PCI, and this event is associated with an increased infarct size, reduced recovery of ventricular function, and increased mortality.<sup>7-11</sup>

Microvascular obstruction is related to the embolization of plaque or thrombotic material downstream in the infarct-related artery.<sup>12,13</sup> Embolization can occur spontaneously or by means of mechanical fragmentation during PCI.<sup>12-15</sup> One coronary angiographic technique used to assess perfusion in the myocardial tissue is myocardial blush grading.<sup>7,9,11</sup> In clinical practice, electrocardiographic (ECG) analysis of the degree of resolution of ST-segment elevation after PCI is often used.<sup>8,10,11</sup>

The high frequency of suboptimal myocardial reperfusion after primary PCI has resulted in the development of various devices to protect the microcirculation.<sup>16-24</sup> A 6-French-compatible manual-aspiration catheter is practical for this purpose, since it is relatively flexible and nontraumatic in use. Many previous trials have used findings on coronary angiography as selection criteria and have not performed a systematic analysis of the material retrieved during aspiration. We therefore evaluated the use of a manual-aspiration catheter to improve myocardial perfusion during primary PCI in patients with myocardial infarction with ST-segment elevation. Our patients were randomly assigned to a treatment group before coronary angiography was performed and therefore without consideration of angiographic selection criteria (such as the presence of a visible thrombus on angiography), and we conducted a histopathological analysis of the retrieved material as an additional evaluation of procedural efficacy.<sup>25</sup>

## METHODS

### STUDY DESIGN AND POPULATION

The Thrombus Aspiration during Percutaneous Coronary Intervention in Acute Myocardial Infarc-

tion Study (TAPAS) was a single-center, prospective, randomized, open trial involving the blinded evaluation of end points.<sup>25</sup> The institutional review board of the University Medical Center Groningen (Groningen, the Netherlands) approved the study. All patients provided written informed consent.

All consecutive patients presenting to the University Medical Center Groningen with a possible myocardial infarction with ST-segment elevation between January 2005 and December 2006 were considered eligible for participation. The inclusion criteria were symptoms suggesting acute myocardial ischemia lasting more than 30 minutes, the onset of symptoms less than 12 hours previously, and ST-segment elevation of more than 0.1 mV in two or more leads on the ECG. The exclusion criteria were the performance of a rescue PCI after thrombolysis, the known existence of a disease resulting in a life expectancy of less than 6 months, and the lack of informed consent.

### RANDOMIZATION AND TREATMENT

Before diagnostic angiography was performed, patients were randomly assigned to undergo thrombus aspiration during PCI or conventional PCI, with the use of a computerized voice-response system. The randomization code was developed by means of a number generator used to select randomly permuted blocks of three to six patients, which were then stratified by the interventional cardiologist to achieve a balanced group assignment with regard to both the treatment group and the cardiologist performing the procedure.<sup>25</sup>

For all patients, the first procedural step was the passing of a floppy, steerable guidewire through the target lesion. In patients in the conventional-PCI group, this step was followed by balloon dilation to establish antegrade flow. In patients in the thrombus-aspiration group, this step was followed by the advancing of the 6-French Export Aspiration Catheter (Medtronic; crossing profile, 0.068 in.) into the target coronary segment during continuous aspiration; when necessary for stent delivery, balloon dilation was performed before stenting. In all patients, after the restoration of antegrade flow, intracoronary nitrates were given to ensure maximal epicardial vasodilation, in order to determine the size and length of the stent and to facilitate stent placement. All placed stents were bare-metal stents.

Pharmacologic treatment before PCI included the administration of aspirin (a loading dose of

**Figure 1. Enrollment, Group Assignments, and Follow-up of Patients.**

Conservative treatment was treatment that did not include percutaneous coronary intervention (PCI) or coronary-artery bypass grafting (CABG). STEMI denotes myocardial infarction with ST-segment elevation.

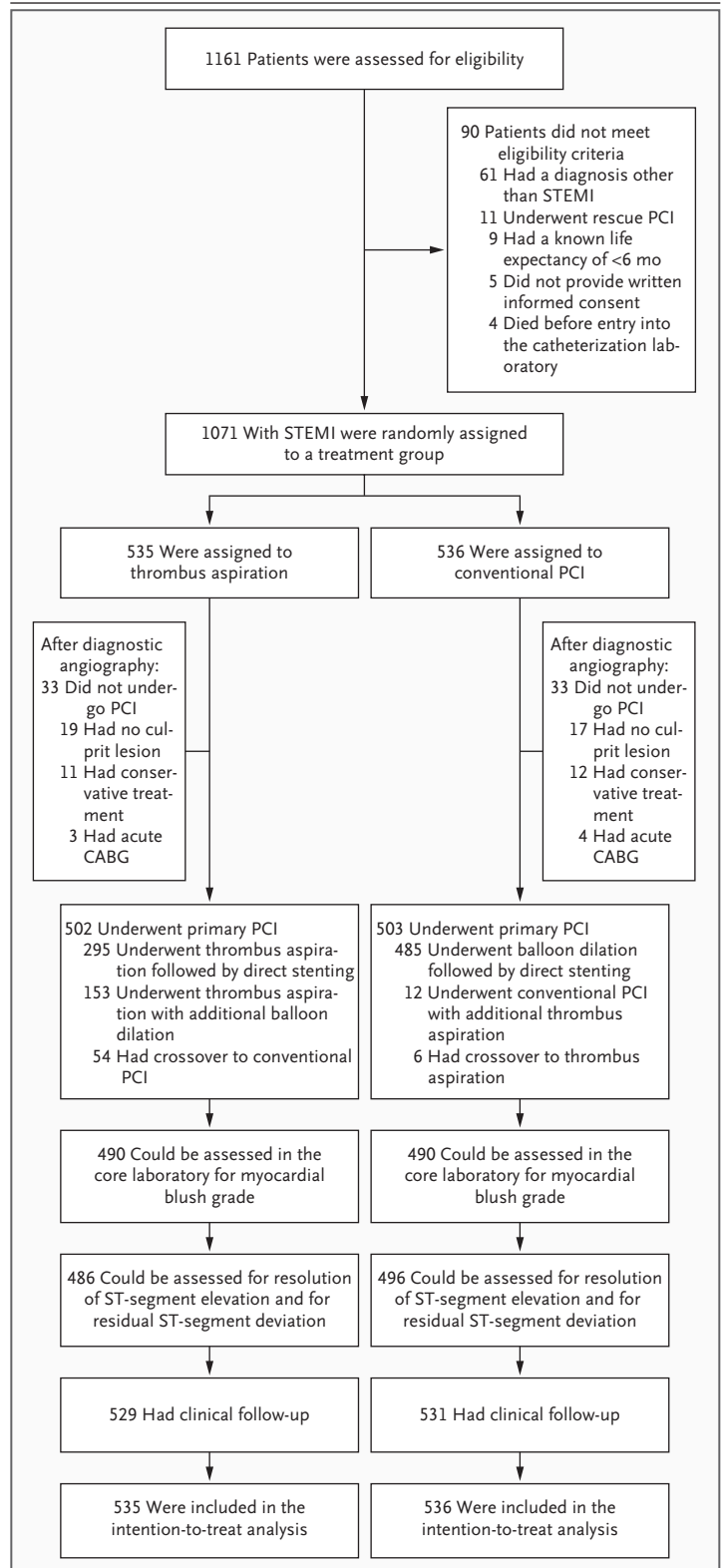
500 mg), heparin (5000 IU), and clopidogrel (a loading dose of 600 mg). Patients also received the glycoprotein IIb/IIIa inhibitor abciximab, with the dose based on body weight, unless contraindicated, and additional heparin, with the dose based on the activated clotting time. Standard therapies after PCI included aspirin, clopidogrel, beta-blockers, lipid-lowering agents, and angiotensin-converting-enzyme inhibitors or angiotensin-II-receptor blockers, according to current guidelines.<sup>6</sup>

**END POINTS, ASSESSMENT OF OUTCOMES, AND DEFINITIONS**

The primary end point was the postprocedural frequency of a myocardial blush grade of 0 or 1 as detailed below.<sup>25</sup> Secondary end points were the postprocedural frequencies of a Thrombolysis in Myocardial Infarction (TIMI) flow grade of 3, complete resolution of ST-segment elevation, the absence of persistent ST-segment deviation, target-vessel revascularization, reinfarction, death, and the combination of major adverse cardiac events by 30 days after randomization.

Coronary angiography was performed before and after the PCI. TIMI flow grades were assessed as previously described.<sup>26</sup> Myocardial blush grades were assigned as previously described by Van 't Hof et al.<sup>7</sup>: 0, no myocardial blush; 1, minimal myocardial blush or contrast density; 2, moderate myocardial blush or contrast density but less than that obtained during angiography of a contralateral or ipsilateral non-infarct-related coronary artery; and 3, normal myocardial blush or contrast density, similar to that obtained during angiography of a contralateral or ipsilateral non-infarct-related coronary artery. Persistent myocardial blush suggests leakage of contrast medium into the extravascular space and is given a grade of 0. Angiographic evidence of a thrombus was assessed according to the criteria summarized by Mabin et al.<sup>27</sup> Data from the coronary angiogram were analyzed at an independent core laboratory (Cordinamo).<sup>25</sup>

A 12-lead ECG was acquired at presentation and 30 to 60 minutes after PCI, and the ST-seg-



ments on the postprocedural ECG were compared with those on the ECG at presentation. The degree of resolution of ST-segment elevation was cate-

<b>Table 1. Baseline Characteristics of the Patients.*</b>			
<b>Characteristic</b>	<b>Thrombus Aspiration (N = 535)</b>	<b>Conventional PCI (N = 536)</b>	<b>P Value</b>
<b>Clinical</b>			
Age — yr	63±13	63±13	0.36
Male sex — no. (%)	363 (67.9)	392 (73.1)	0.06
History — no./total no. (%)			
Hypertension	171/517 (33.1)	195/526 (37.1)	0.18
Diabetes mellitus	56/530 (10.6)	67/532 (12.6)	0.30
Hypercholesterolemia	115/485 (23.7)	130/480 (27.1)	0.23
Myocardial infarction	50/528 (9.5)	57/533 (10.7)	0.51
PCI	39/526 (7.4)	38/531 (7.2)	0.87
CABG	17/529 (3.2)	22/533 (4.1)	0.43
Cerebrovascular disease	17/517 (3.3)	21/522 (4.0)	0.53
Cardiovascular disease in family	235/509 (46.2)	229/514 (44.6)	0.58
Current smoking — no./total no. (%)	213/463 (46.0)	225/469 (48.0)	0.57
Preinfarction angina — no./total no. (%)	258/483 (53.4)	233/476 (48.9)	0.17
Total ischemic time — min			
Median	190	185	0.61
Interquartile range	110–270	107–263	
Body-mass index†	27±4	27±4	0.69
Systolic blood pressure — mm Hg	128±26	130±26	0.34
Diastolic blood pressure — mm Hg	74±15	75±16	0.65
Heart rate — bpm	78±18	78±19	0.98
<b>Angiographic</b>			
No. of diseased vessels — no./total no. (%)			0.84
0	13/533 (2.4)	10/534 (1.9)	
1	166/533 (31.1)	157/534 (29.4)	
2	175/533 (32.8)	174/534 (32.6)	
3	178/533 (33.4)	193/534 (36.1)	
Infarct-related vessel — no./total no. (%)			
Left anterior descending artery	221/515 (42.9)	223/517 (43.1)	0.62
Left circumflex artery	93/515 (18.1)	79/517 (15.3)	
Right coronary artery	189/515 (36.7)	204/517 (39.5)	
Other	12/515 (2.3)	11/517 (2.1)	
TIMI flow grade — no./total no. (%)			
0 or 1	288/526 (54.8)	316/531 (59.5)	0.23
2	102/526 (19.4)	85/531 (16.0)	
3	136/526 (25.9)	130/531 (24.5)	
Thrombus — no./total no. (%)	252/519 (48.6)	233/529 (44.0)	0.14
<b>Procedural</b>			
Time from hospital entry to first balloon inflation or aspiration — min			0.92
Median	28	26	
Interquartile range	14–42	12–40	

Table 1. (Continued.)

Characteristic	Thrombus Aspiration (N = 535)	Conventional PCI (N = 536)	P Value
Duration of fluoroscopy — min			0.64
Median	7	7	
Interquartile range	4.5–9.5	4.5–9.5	
Administration of glycoprotein IIb/IIIa inhibitor — no./total no. (%)	469/502 (93.4)	452/503 (89.9)	0.12
Stent implantation — no./total no. (%)	442/479 (92.3)	438/476 (92.0)	0.88
Length of stented segment — mm	18.5±8.7	18.6±8.9	0.48
Diameter of stented segment — mm	3.0±1.1	3.0±1.1	0.68
Intra-aortic balloon pump — no./total no. (%)	23/479 (4.8)	35/470 (7.4)	0.09
Postprocedural TIMI flow grade 3 — no./total no. (%)	431/501 (86.0)	409/496 (82.5)	0.12
Intraprocedural complications — no./total no. (%)			
Side-branch occlusion	5/502 (1.0)	4/503 (0.8)	1.00
Flow-limiting dissections	0	0	1.00
Emergency CABG	1/502 (0.2)	1/503 (0.2)	1.00

\* Plus-minus values are means ±SD. Data for total ischemic time were available for 492 patients in the thrombus-aspiration group and 488 patients in the conventional percutaneous-coronary-intervention (PCI) group; for body-mass index, 488 and 490 patients, respectively; for systolic and diastolic blood pressures, 514 and 522; for heart rate, 512 and 522; for time from hospital entry to first balloon inflation or aspiration, 502 and 503; for duration of fluoroscopy, 490 and 495; and for length and diameter of stented segment, 479 and 476. CABG denotes coronary-artery bypass grafting, and TIMI Thrombolysis in Myocardial Infarction.

† The body-mass index is the weight in kilograms divided by the square of the height in meters.

gorized as complete (>70%), partial (30 to 70%), or none (<30%).<sup>8</sup> Persistent ST-segment deviation, defined as the sum of the ST-segment depression and the ST-segment elevation, was categorized as less than 2 mm, 2 to 10 mm, and more than 10 mm. The presence or absence of pathologic Q waves was also recorded.

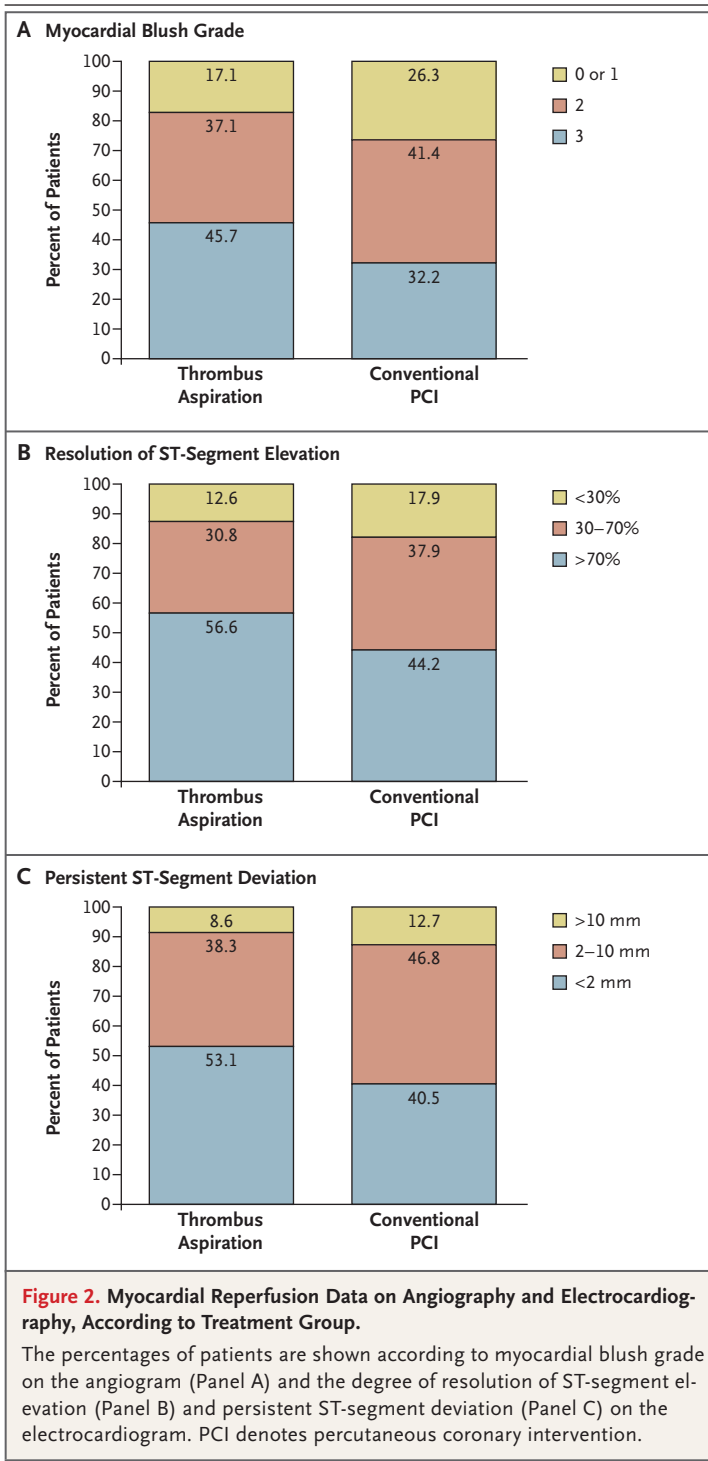
Filtered, aspirated material was fixed in formalin for 24 hours. Histologic sections were cut and stained with hematoxylin and eosin for examination with a light microscope (magnification, ×100). Immunostaining was performed to optimize the visualization of smooth-muscle cells and macrophage foam cells. Aspiration was defined as effective or not effective on the basis of the presence of atherothrombotic material in the aspirate samples. The material was classified as from a thrombus containing only platelets, a thrombus with an erythrocyte component, or a thrombus with plaque, as well as according to length: small (<0.5 mm), moderate (0.5 to 2 mm), or large (>2 mm).

Follow-up data at 30 days were obtained from hospital records and through telephone interviews. Major bleeding was defined as symptomatic bleed-

ing in a critical area or organ, bleeding causing a decrease in hemoglobin level of 2.0 mmol or more per liter, or bleeding that led to blood transfusion. Reinfarction was defined as recurrent symptoms with new ST-segment elevation and elevation of the levels of cardiac markers to at least twice the upper limit of the normal range. Target-vessel revascularization was defined as ischemia-driven revascularization of the infarct-related artery, performed by means of PCI or surgery (e.g., coronary-artery bypass grafting) during the follow-up period. A major adverse cardiac event was defined as death, reinfarction, or target-vessel revascularization.

#### STATISTICAL ANALYSIS

We estimated that we would have to enroll 1080 patients to achieve a power of 80%, with a two-sided significance level of 0.05, to detect a 25% reduction in the primary end point in patients who underwent thrombus aspiration as compared with those who underwent conventional PCI, assuming a 30% rate of myocardial blush grade of 0 or 1 in the conventional-PCI group.<sup>25</sup> The study com-



mittee (see the Appendix) performed a planned interim analysis after 300 patients had been enrolled. The stopping limit was a difference of more than 25% in the primary end point between the two groups, with a P value of less than 0.01.

Categorical variables were compared with the use of the chi-square test or Fisher's exact test. Continuous variables were compared with the use of a two-tailed Student's t-test. Prespecified subgroup analyses were performed by means of logistic-regression analyses with formal tests for interaction.<sup>28</sup> We analyzed data for all patients who were randomly assigned to a treatment group and for whom outcome data were available. Exploratory analyses of the association between the surrogate and clinical end points were performed by means of logistic-regression analysis. Two-sided significance tests were used. P values of less than 0.05 were considered to indicate statistical significance. SPSS software, version 12.0.1, was used in all statistical analyses.

Data management and statistical analyses were performed by staff of the data coordinating center (see the Appendix) and the principal investigator, who vouches for the accuracy and completeness of the data.

## RESULTS

### STUDY POPULATION

During the study period, 1161 patients were considered for inclusion, and 1071 patients were enrolled according to the eligibility criteria (Fig. 1). Before coronary angiography, patients were randomly assigned to undergo either thrombus aspiration during PCI (535 patients) or conventional PCI (536 patients). The baseline clinical and angiographic characteristics were similar in the two groups (Table 1).

### PROCEDURAL DATA

On the basis of the initial angiographic findings, 33 patients (approximately 6%) in each group did not undergo PCI. In the thrombus-aspiration group, aspiration and direct stent implantation were performed in 295 patients (55.1%), balloon dilation was performed before stent implantation in 153 patients (28.6%), and conventional PCI was performed in 54 patients (10.1%) in whom the operator judged the target artery to be too small or too tortuous to permit use of the aspiration catheter (Fig. 1).

Data about the procedures and intraprocedural complications are shown in Table 1. None of the complications were thought to be related to the aspiration device used. There were no intraprocedural deaths or strokes.

**MYOCARDIAL REPERFUSION**

The postprocedural myocardial blush grade could be assessed in 980 (490 in each group) of the 1005 patients (97.5%) who underwent PCI. A myocardial blush grade of 0 or 1 occurred in 84 of the 490 patients (17.1%) in the thrombus-aspiration group and in 129 of the 490 patients (26.3%) in the conventional-PCI group (risk ratio, 0.65; 95% confidence interval [CI], 0.51 to 0.83;  $P < 0.001$ ) (Fig. 2A).

The ECGs obtained at baseline and after the procedure were analyzed in 982 of the 1005 patients (97.7%) who underwent PCI. The median time from treatment to the postprocedural ECG was 44 minutes (interquartile range, 25 to 63) in the thrombus-aspiration group and 43 minutes (interquartile range, 25 to 61) in the conventional-PCI group ( $P = 0.40$ ). Complete ST-segment resolution occurred in 275 of the 486 patients (56.6%) in the thrombus-aspiration group and 219 of the 496 patients (44.2%) in the conventional-PCI group (risk ratio, 1.28; 95% CI, 1.13 to 1.45;  $P < 0.001$ ) (Fig. 2B). Similarly, 258 of the 486 patients (53.1%) in the thrombus-aspiration group had no persistent ST-segment deviation, as compared with 201 of the 496 patients (40.5%) in the conventional-PCI group (risk ratio, 1.31; 95% CI, 1.14 to 1.50;  $P < 0.001$ ) (Fig. 2C). In the thrombus-aspiration group, 119 of 486 patients (24.5%) did not have pathologic Q waves on the ECG, as compared with 79 of 496 patients (15.9%) in the conventional-PCI group (risk ratio, 1.54; 95% CI, 1.19 to 1.99;  $P = 0.001$ ).

There was no evidence that the benefit with regard to the primary end point was heterogeneous among the baseline levels of the prespecified covariates. There were no significant interactions for any subgroups (Fig. 3).

**HISTOPATHOLOGICAL FEATURES**

Table 2 shows the rate of retrieval and the histopathological characteristics and size of the aspirate, according to initial angiographic findings in the patients who underwent aspiration. Histopathological examination was performed in 454 patients, which in 331 patients (72.9%) showed atherothrombotic material.

**CLINICAL OUTCOME AT 30 DAYS**

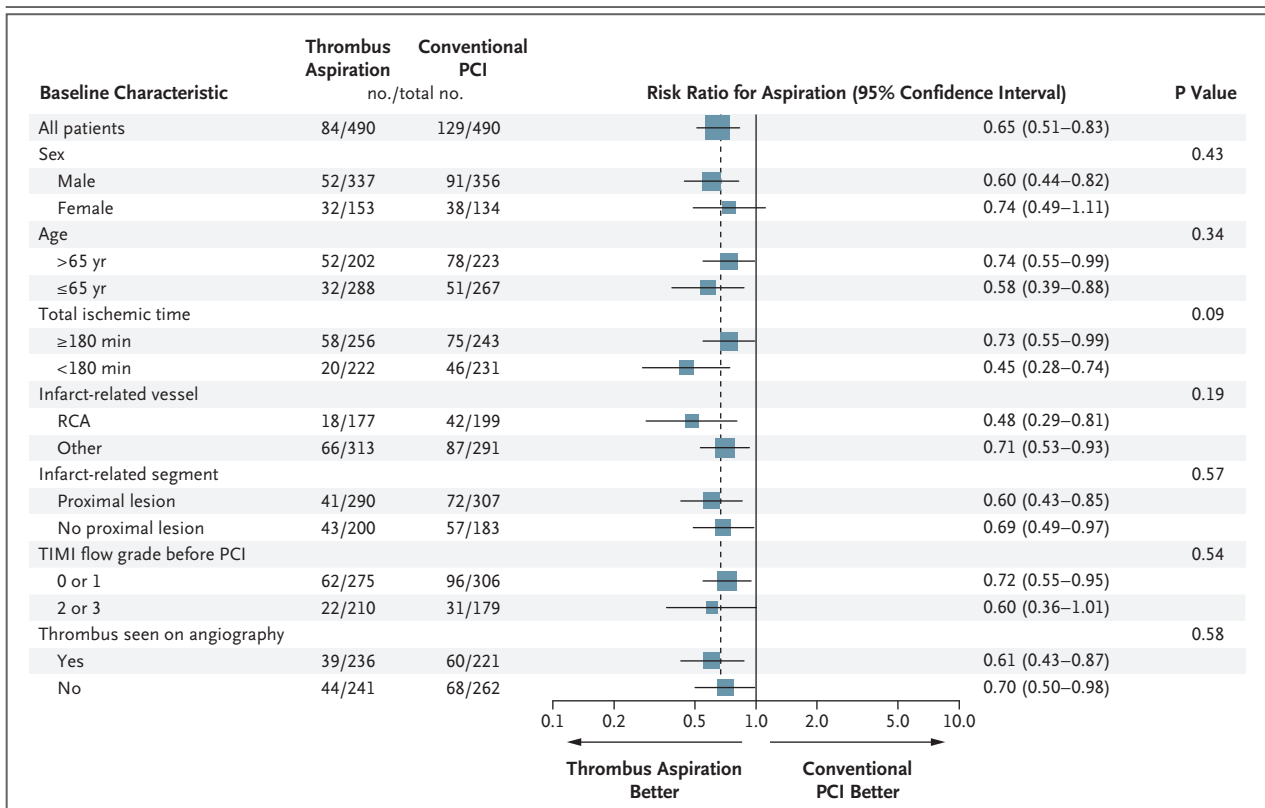
In the thrombus-aspiration group and the conventional-PCI group, there was major bleeding in 20 of 529 patients (3.8%) and 18 of 531 patients

(3.4%), respectively (risk ratio, 1.11; 95% CI, 0.60 to 2.08;  $P = 0.11$ ); death in 11 of 529 (2.1%) and 21 of 531 (4.0%) (risk ratio, 0.52; 95% CI, 0.26 to 1.07;  $P = 0.07$ ); reinfarction in 4 of 529 (0.8%) and 10 of 531 (1.9%) (risk ratio, 0.40; 95% CI, 0.13 to 1.27;  $P = 0.11$ ); target-vessel revascularization in 24 of 529 (4.5%) and 31 of 531 (5.8%) (risk ratio, 0.77; 95% CI, 0.46 to 1.30;  $P = 0.34$ ); and major adverse cardiac events at 30 days in 36 of 529 (6.8%) and 50 of 531 (9.4%) (risk ratio, 0.72; 95% CI, 0.48 to 1.08;  $P = 0.12$ ). The rates of death and major adverse cardiac events at 30 days were both significantly related to myocardial blush grade, resolution of ST-segment elevation, and ST-segment deviation ( $P = 0.003$  for the association between death and myocardial blush grade;  $P < 0.001$  for all other associations) (Fig. 4).

**DISCUSSION**

The results of our randomized trial show that effective manual aspiration of atherothrombotic material is feasible in a large majority of patients presenting with myocardial infarction with ST-segment elevation. As compared with balloon angioplasty as an initial step in primary PCI, aspiration before stenting results in improved myocardial reperfusion, documented by a clear improvement in the myocardial blush grade, increased resolution of ST-segment elevation, and reduced residual ST-segment deviation. This beneficial effect of aspiration was consistently present in all patients, irrespective of baseline clinical or angiographic characteristics such as age, sex, infarct-related coronary artery, preprocedural TIMI flow, or visible thrombus on the angiogram. Atherothrombotic material was retrieved in 73% of the patients who underwent thrombus aspiration, and the main constituent of the retrieved material was platelets.

Our data confirm the prognostic value of the myocardial blush grade and degree of resolution of the ST-segment elevation after reperfusion therapy, since these variables were strongly related to the 30-day rates of death and major adverse cardiac events.<sup>7,8</sup> The trends we found for these rates were expected from the differences between the two groups in variables reflecting myocardial reperfusion. Since a larger proportion of patients in the thrombus-aspiration group than in the conventional-PCI group did not have pathologic Q waves on the postprocedural ECG, this



**Figure 3. Risk Ratios for the Primary End Point, According to Prespecified Clinical or Angiographic Subgroup.**

Data are reported for the patients who had clinical and coronary angiographic data at baseline. PCI denotes percutaneous coronary intervention, RCA right coronary artery, and TIMI Thrombolysis in Myocardial Infarction.

benefit may be mediated, at least in part, by myocardial salvage.

The clinical importance of embolization of atherothrombotic material from unstable plaques in patients with myocardial infarction with ST-segment elevation has been recognized,<sup>12,13</sup> and embolic protection during PCI in such patients has been tested with various devices in small or medium-sized trials, with diverse results.<sup>16–24</sup> This variation in results may be in part related to the device used, since trials involving manual-aspiration devices have all shown favorable effects of aspiration on myocardial-perfusion variables.<sup>20–22</sup> Most of the previous trials have enrolled patients who were selected on the basis of angiographic features,<sup>16–19,21–24</sup> since it was assumed that patients with a large thrombotic burden are identified on angiography and will particularly benefit from the treatment. Our data show that angiographic variables such as TIMI flow or the presence of a visible thrombus are not predictors of patients in whom aspiration will be effective. Our

findings therefore support the concept that the presence of a thrombus plays an important role in the pathophysiological characteristics of most patients with myocardial infarction with ST-segment elevation.

We powered our trial on the assumption of a 25% reduction in the frequency of myocardial blush grade of 0 or 1 in the thrombus-aspiration group. Our data confirm a benefit of this magnitude, albeit with a somewhat lower incidence of myocardial blush grade of 0 or 1 in the conventional-PCI group than expected: 26.4% instead of 30%. This may be explained by the administration of pharmacotherapy immediately after the diagnosis of myocardial infarction with ST-segment elevation was made, followed by the use of abciximab at the start of the PCI procedure.

Our trial provides a systematic analysis of the role of coronary thrombi in a representative, contemporary population with myocardial infarction with ST-segment elevation, since aspiration was performed soon after the onset of symptoms in

**Table 2. Histopathological Characteristics of Coronary-Artery Thrombi from Initial Findings on Coronary Angiography in Patients Undergoing Thrombus Aspiration.\***

Characteristic	No. of Patients	Infarct-Related Vessel				TIMI Flow Grade		Thrombus Seen	
		LAD	Cx	RCA	Other	0 or 1	2 or 3	Yes	No
Total no. of patients	454	201	75	171	7	265	185	225	217
Aspirate collected — no. (%)	331 (72.9)	138 (68.7)	49 (65.3)	140 (81.9)	4 (57.1)	201 (75.8)	127 (68.6)	173 (76.9)	146 (67.3)
Composition of aspirate									
Platelet — no. (%)	224 (67.7)	101	33	88	2	120	101	116	100
<0.5 mm — %	70.5	72.3	72.7	67.0	100.0	68.3	74.3	67.2	76.0
0.5–2.0 mm — %	24.1	21.8	18.2	29.6	0	27.5	18.8	29.3	17.0
>2.0 mm — %	5.4	5.9	9.1	3.4	0	4.2	6.9	3.5	7.0
Erythrocyte — no. (%)	50 (15.1)	14	8	26	2	45	5	32	15
<0.5 mm — %	4.0			7.7	0	4.4		6.3	
0.5–2.0 mm — %	22.0	42.9	25.0	11.5	0	24.4		18.7	33.3
>2.0 mm — %	74.0	57.1	75.0	80.8	100.0	71.2	100.0	75.0	66.7
Plaque — no. (%)	57 (17.2)	23	8	26	0	36	21	25	31
<0.5 mm — %	33.3	39.1	25.0	30.8		30.6	38.1	28.0	38.7
0.5–2.0 mm — %	45.6	34.8	62.5	50.0		44.4	47.6	48.0	41.9
>2.0 mm — %	21.1	26.1	12.5	19.2		25.0	14.3	24.0	19.4

\* The 454 patients undergoing thrombus aspiration were 448 patients in the thrombus-aspiration group and 6 patients in the conventional percutaneous-coronary-intervention group. Data are reported for the patients who had coronary angiographic data at baseline. "Platelet" was defined as a thrombus composed only of platelets, "erythrocyte" as a thrombus with bands of erythrocytes, and "plaque" as a thrombus with any fragment of vessel wall, cholesterol crystals, inflammatory cells, or collagen tissue. All millimeter measurements refer to length. Cx denotes left circumflex artery, LAD left anterior descending artery, and RCA right coronary artery.

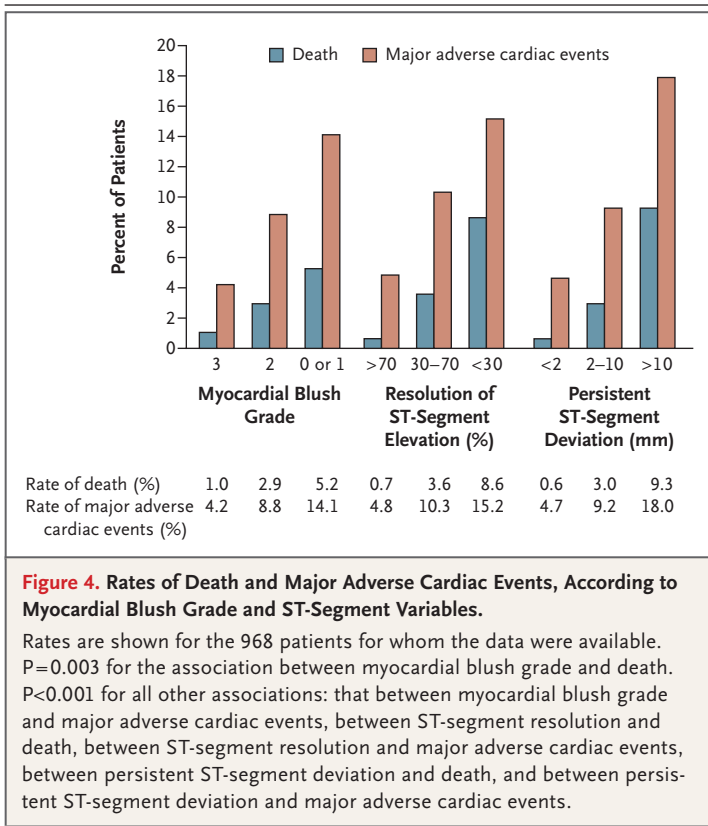
a large cohort of patients who were not selected on the basis of angiographic characteristics and were randomly assigned to a treatment group. The rate of retrieval of atherothrombotic material (73%) is somewhat lower than that reported in smaller, nonrandomized pathological thrombectomy studies of patients who had myocardial infarction with ST-segment elevation,<sup>13,29</sup> possibly because of the selection of patients and angiographic characteristics or differences in the devices and antithrombotic regimens used.

Our histopathological findings confirm earlier observations that thrombi predominantly composed of platelets are common in patients who have myocardial infarction with ST-segment elevation.<sup>13,29,30</sup> Platelets are thought to play an important role in embolization and microvascular dysfunction.<sup>12,31</sup> Mechanical removal of a thrombus before PCI reduces the existing source of embolization but does not address platelet aggregates generated after PCI. These can be abolished with the use of platelet inhibitors.<sup>32</sup> It is therefore possible that the combined use of aspiration and gly-

coprotein IIb/IIIa inhibitors will have a synergistic effect.

The platelet thrombi were mostly small or moderate in size, whereas the erythrocyte-rich thrombi were moderate or large in size. This may reflect the process whereby a platelet thrombus forms by means of the adherence and aggregation of platelets on a disrupted lesion, followed by the development of thrombus through the deposition of erythrocytes in the stagnant blood flow over the platelet thrombus.<sup>1,33,34</sup> The association between large erythrocyte-rich thrombi and a TIMI flow grade of 0 or 1 before PCI is consistent with this mechanism.

We could not identify atherothrombotic material in 27% of patients in whom aspiration was performed. This may be due to a variety of mechanisms. First, a thrombus may be dissolved by endogenous or pharmacologic antithrombotic or fibrinolytic agents. Second, a thrombus may break off and embolize before PCI or during PCI, owing to the guidewire or aspiration device. In some patients in our trial, mechanical resistance at the



**Figure 4. Rates of Death and Major Adverse Cardiac Events, According to Myocardial Blush Grade and ST-Segment Variables.**

Rates are shown for the 968 patients for whom the data were available.  $P=0.003$  for the association between myocardial blush grade and death.  $P<0.001$  for all other associations: that between myocardial blush grade and major adverse cardiac events, between ST-segment resolution and death, between ST-segment resolution and major adverse cardiac events, between persistent ST-segment deviation and death, and between persistent ST-segment deviation and major adverse cardiac events.

site of occlusion prevented passage of the aspiration device through the infarct-related segment. It seems likely that, in some patients who have myocardial infarction with ST-segment elevation, a high-grade, nonthrombotic, unstable atherosclerotic plaque causes the coronary obstruction (e.g., a plaque with hemorrhage).<sup>33,34</sup> The patients who did not have a response to aspiration might also not have shown reperfusion after thrombolytic therapy. Third, within hours after formation, a thrombus may be covered by mononuclear cells that stop the deposition of platelets.<sup>35</sup> Finally, fragile material may disintegrate while passing through the catheter or filter or in the collection bottle.

Our trial has several limitations. First, it represents a single-center experience using surrogate end points. However, the fact that the surrogate end points of myocardial blush grade and the electrocardiographic variables of reperfusion were clearly associated with the rates of death and ma-

ior adverse cardiac events supports the validity of using such end points in studies of patients who have myocardial infarction with ST-segment elevation. Second, to prevent selection bias, we performed randomization before coronary angiography. As a consequence, some patients did not undergo PCI or received the alternative therapy. This may have diluted to some extent the positive effects of aspiration, but it makes our findings applicable to a general population with myocardial infarction with ST-segment elevation. Third, it cannot be ruled out that extractable thrombi differ from thrombi in situ. Finally, it has been suggested that primary stenting without balloon predilation in patients who have myocardial infarction with ST-segment elevation results in improved distal flow and reduced embolization. Our study was not designed to evaluate the effect of dilation before stenting. This issue needs further investigation in a randomized setting.

In conclusion, we found that manual thrombus aspiration can be performed in a large majority of patients presenting with myocardial infarction with ST-segment elevation, irrespective of their clinical and angiographic features (e.g., a visible thrombus on angiography) and results in improved myocardial reperfusion and clinical outcome as compared with conventional PCI. The significant relationship we found between myocardial and electrocardiographic variables of reperfusion and the rates of death and major adverse cardiac events supports the validity of these reperfusion variables as surrogate end points in patients who have myocardial infarction with ST-segment elevation. The histopathological findings in the aspirate specimens underline the importance of antiplatelet therapy in improving the outcome after primary PCI.

Supported by a grant from Medtronic (for angiographic analyses by the core laboratory). All other costs were covered by the Thorax Center of the University Medical Center Groningen. There were no other relationships between the investigators and companies that make the products studied or discussed in this article or related products.

No potential conflict of interest relevant to this article was reported.

We thank the staff of the catheterization laboratory and the coronary care unit for their support in the acute care setting, A. Dijk and M. Vogelzang for assistance with data management, and Dr. H. Hillege for statistical advice.

#### APPENDIX

Members of the study committee were F. Zijlstra (chair), T. Svilaas (principal investigator), I.C. van der Horst, and P.J. Vlaar. The interventional cardiologists were R.L. Anthonio, A.F.M. van den Heuvel, G.A. Jessurun, B.J.G.L. de Smet, E.-S. Tan, and F. Zijlstra; staff of the pathology laboratory were A.J.H. Suurmeijer and G.F.H. Diercks. The data coordinating center was the Trial Coordination Center, Department of Epidemiology, University Medical Center Groningen, Groningen, the Netherlands. The angiographic core laboratory was Cordinamo, Wezep, the Netherlands (D. Amo, director).

## REFERENCES

- Falk E. Plaque rupture with severe pre-existing stenosis precipitating coronary thrombosis: characteristics of coronary atherosclerotic plaques underlying fatal occlusive thrombi. *Br Heart J* 1983;50:127-34.
- Davies MJ, Thomas A. Thrombosis and acute coronary-artery lesions in sudden cardiac ischemic death. *N Engl J Med* 1984;310:1137-40.
- DeWood MA, Spores J, Notske R, et al. Prevalence of total coronary occlusion during the early hours of transmural myocardial infarction. *N Engl J Med* 1980;303:897-902.
- Zijlstra F, Hoorntje JC, de Boer MJ, et al. Long-term benefit of primary angioplasty as compared with thrombolytic therapy for acute myocardial infarction. *N Engl J Med* 1999;341:1413-9.
- Keeley EC, Boura JA, Grines CL. Primary angioplasty versus intravenous thrombolytic therapy for acute myocardial infarction: a quantitative review of 23 randomised trials. *Lancet* 2003;361:13-20.
- Silber S, Albertsson P, Avilés FF, et al. Guidelines for percutaneous coronary interventions: the Task Force for Percutaneous Coronary Interventions of the European Society of Cardiology. *Eur Heart J* 2005;26:804-47.
- Van 't Hof AW, Liem A, Suryapranata H, Hoorntje JC, de Boer MJ, Zijlstra F. Angiographic assessment of myocardial reperfusion in patients treated with primary angioplasty for acute myocardial infarction: myocardial blush grade. *Circulation* 1998;97:2302-6.
- Van 't Hof AW, Liem A, de Boer MJ, Zijlstra F. Clinical value of 12-lead electrocardiogram after successful reperfusion therapy for acute myocardial infarction. *Lancet* 1997;350:615-9.
- Stone GW, Peterson MA, Lansky AJ, Dangas G, Mehran R, Leon MB. Impact of normalized myocardial perfusion after successful angioplasty in acute myocardial infarction. *J Am Coll Cardiol* 2002;39:591-7.
- McLaughlin MG, Stone GW, Aymong E, et al. Prognostic utility of comparative methods for assessment of ST-segment resolution after primary angioplasty for acute myocardial infarction: the Controlled Abciximab and Device Investigation to Lower Late Angioplasty Complications (CADILLAC) trial. *J Am Coll Cardiol* 2004;44:1215-23.
- Poli A, Fèveau R, Vandoni P, et al. Integrated analysis of myocardial blush and ST-segment elevation recovery after successful primary angioplasty: real-time grading of microvascular reperfusion and prediction of early and late recovery of left ventricular function. *Circulation* 2002;106:313-8.
- Topol EJ, Yadav JS. Recognition of the importance of embolization in atherosclerotic vascular disease. *Circulation* 2000;101:570-80.
- Kotani J, Nanto S, Mintz GS, et al. Plaque gruel of atheromatous coronary lesion may contribute to the no-reflow phenomenon in patients with acute coronary syndrome. *Circulation* 2002;106:1672-7.
- Henriques JP, Zijlstra F. Frequency and sequelae of ST elevation acute myocardial infarction caused by spontaneous distal embolization from unstable coronary lesions. *Am J Cardiol* 2003;91:708-11.
- Henriques JP, Zijlstra F, Ottervanger JP, et al. Incidence and clinical significance of distal embolization during primary angioplasty for acute myocardial infarction. *Eur Heart J* 2002;23:1112-7.
- Napodano M, Pasquetto G, Saccà S, et al. Intracoronary thrombectomy improves myocardial reperfusion in patients undergoing direct angioplasty for acute myocardial infarction. *J Am Coll Cardiol* 2003;42:1395-402.
- Antoniucci D, Valenti R, Migliorini A, et al. Comparison of rheolytic thrombectomy before direct infarct artery stenting versus direct stenting alone in patients undergoing percutaneous coronary intervention for acute myocardial infarction. *Am J Cardiol* 2004;93:1033-5.
- Lefèvre T, Garcia E, Reimers B, et al. X-sizer for thrombectomy in acute myocardial infarction improves ST-segment resolution. *J Am Coll Cardiol* 2005;46:246-52.
- Stone GW, Webb J, Cox DA, et al. Distal microcirculatory protection during percutaneous coronary intervention in acute ST-segment elevation myocardial infarction: a randomized controlled trial. *JAMA* 2005;293:1063-72.
- Burzotta F, Trani C, Romagnoli E, et al. Manual thrombus-aspiration improves myocardial reperfusion: the randomized evaluation of the effect of mechanical reduction of distal embolization by thrombus-aspiration in primary and rescue angioplasty (REMEDIA) trial. *J Am Coll Cardiol* 2005;46:371-6.
- De Luca G, Suryapranata H, Chiariello M, et al. Aspiration thrombectomy and primary percutaneous coronary intervention. *Heart* 2006;92:867-9.
- Silva-Orrego P, Colombo P, Bigi R, et al. Thrombus aspiration before primary angioplasty improves myocardial reperfusion in acute myocardial infarction: the DEAR-MI (Dethrombosis to Enhance Acute Reperfusion in Myocardial Infarction) study. *J Am Coll Cardiol* 2006;48:1552-9.
- Ali A, Cox D, Dib N, et al. Rheolytic thrombectomy with percutaneous coronary intervention for infarct size reduction in acute myocardial infarction: 30-day results from a multicenter randomized study. *J Am Coll Cardiol* 2006;48:244-52.
- Kaltoft A, Botcher M, Nielsen SS, et al. Routine thrombectomy in percutaneous coronary intervention for acute ST-segment-elevation myocardial infarction: a randomized, controlled trial. *Circulation* 2006;114:40-7.
- Svilaas T, van der Horst IC, Zijlstra F. Thrombus Aspiration during Percutaneous coronary intervention in Acute myocardial infarction Study (TAPAS) — study design. *Am Heart J* 2006;151(3):597.e1-597.e7.
- The TIMI Study Group. The Thrombolysis in Myocardial Infarction (TIMI) trial: phase I findings. *N Engl J Med* 1985;312:932-6.
- Mabin TA, Holmes DR Jr, Smith HC, et al. Intracoronary thrombus: role in coronary occlusion complicating percutaneous transluminal coronary angioplasty. *J Am Coll Cardiol* 1985;5:198-202.
- Altman DG, Bland JM. Interaction revisited: the difference between two estimates. *BMJ* 2003;326:219.
- Rittersma SZ, van der Wal AC, Koch KT, et al. Plaque instability frequently occurs days or weeks before occlusive coronary thrombosis. *Circulation* 2005;111:1160-5.
- Ueda Y, Asakura M, Hirayama A, Komamura K, Hori M, Komada K. Intracoronary morphology of culprit lesions after reperfusion in acute myocardial infarction: serial angiographic observations. *J Am Coll Cardiol* 1996;27:606-10.
- Limbruno U, De Carlo M, Pistolesi S, et al. Distal embolization during primary angioplasty: histopathologic features and predictability. *Am Heart J* 2005;150:102-8.
- Neumann FJ, Blasini R, Schmitt C, et al. Effect of glycoprotein IIb/IIIa receptor blockade on recovery of coronary flow and left ventricular function after the placement of coronary-artery stents in acute myocardial infarction. *Circulation* 1998;98:2695-701.
- Kolodgie FD, Gold HK, Burke AP, et al. Intraplaque hemorrhage and progression of coronary atheroma. *N Engl J Med* 2003;349:2316-25.
- Virmani R, Burke AP, Farb A, Kolodgie FD. Pathology of the vulnerable plaque. *J Am Coll Cardiol* 2006;47:Suppl: C13-C18.
- Joris I, Braunstein PW Jr. Platelets and endothelium: effect of collagen-induced platelet aggregates on pulmonary vessels. *Exp Mol Pathol* 1982;37:393-405.

Copyright © 2008 Massachusetts Medical Society.