

1. Grunfeld C, Thompson M, Brown SJ, et al. Recombinant human growth hormone to treat HIV-associated adipose tissue redistribution syndrome: 12-week induction and 24-week maintenance therapy. *J Acquir Immune Defic Syndr* (in press).
2. Barter PJ, Caulfield M, Eriksson M, et al. Effects of torcetrapib in patients at high risk for coronary events. *N Engl J Med* 2007; 357:2109-22.

Case 32-2007: Bilateral Breast Cancer

TO THE EDITOR: In the case of the woman with a second breast cancer, discussed by Winer et al. (Oct. 18 issue),¹ hereditary breast cancer due to a *BRCA2* mutation should be considered. The patient had two primary breast cancers at an advanced age and had a paternal aunt who had had breast cancer at the age of 90 years. The patient previously had vulvar carcinoma in situ. We and others have seen an increase in cervical and vulvar cancers in carriers of a *BRCA2* mutation and a history of receiving the diagnosis of breast cancer late in life. Some patients also have had ovarian cancers in their 70s.

Patrick J. Morrison, M.D.
Belfast City Hospital
Belfast BT9 6LE, United Kingdom
patrick.morrison@belfasttrust.hscni.net

1. Case Records of the Massachusetts General Hospital (Case 32-2007). *N Engl J Med* 2007;357:1640-8.

THE DISCUSSANTS REPLY: As Dr. Morrison notes, the possibility of a familial predisposition to breast cancer, ovarian cancer, or both should be considered in any patient with breast cancer. It is estimated that 5 to 10% of all breast cancers are hereditary, half of which are related to a germ-line mutation in *BRCA1* or *BRCA2*.¹ Women with *BRCA* mutations are at risk for bilateral breast cancer, and bilateral disease increases the likelihood of

identifying a mutation. Although our patient had bilateral breast cancer, these diagnoses were made at the ages of 56 and 62 years, and there was no other family history of breast or ovarian cancer, apart from a second-degree relative in whom breast cancer had been diagnosed at the age of 90 years. The significance of a past diagnosis of carcinoma in situ of the vulva is unknown. With the use of either the BRCAPRO or Myriad model, the patient has a 2 to 3% chance of harboring a germ-line mutation in *BRCA1* or *BRCA2*.² This level of risk is below the threshold that is generally set for the use of predictive testing,³ and for that reason, neither the clinical service nor the discussants raised the possibility of genetic testing.

Eric P. Winer, M.D.
Jay Harris, M.D.

Dana-Farber and Brigham and Women's Cancer Center
Boston, MA 02115

Barbara L. Smith, M.D., Ph.D.

Massachusetts General Hospital
Boston, MA 02114

1. Garber JE, Offit K. Hereditary cancer predisposition syndromes. *J Clin Oncol* 2005;23:276-92.
2. U.T. Southwestern Medical Center at Dallas, BayesMendel Group at Johns Hopkins. CancerGene, with BRCAPRO, MMRpro, and PancPRO. (Accessed February 7, 2008, at <http://www4.utsouthwestern.edu/breasthealth/cagene/>.)
3. American Society of Clinical Oncology. American Society of Clinical Oncology policy statement update: genetic testing for cancer susceptibility. *J Clin Oncol* 2003;21:2397-406.

Medical Mystery: Cloud Surrounding the Optic Disks — The Answer

The medical mystery in the January 3 issue¹ involved fundus photographs (Fig. 1) showing a yellow cloud surrounding the optic disks of a 42-year-old man. His visual acuity and the examination of the anterior segment of each eye were

normal. The diagnosis is myelinated retinal nerve fibers, a developmental anomaly in which myelination appears beyond the lamina cribrosa or the optic nerve head, on the nerve fibers of the disk and retina. The myelinated fibers appear as stri-

ated white patches with feathery borders, caused by differential myelination of individual axons. Myelinated retinal nerve fibers occur in 1% of the population and may mimic optic-disk swelling or papilledema; an important differentiating feature is the absence of a feathery appearance in true optic-disk swelling. The occurrence is bilateral in 17 to 20% of cases and is continuous with the disk in 81% of cases. Usually, visual acuity is normal, and no particular ophthalmologic follow-up is necessary.

Sandeep Randhawa, M.D.

Andrew G. Lee, M.D.

University of Iowa Hospitals and Clinics
Iowa City, IA 52242
andrew-lee@uiowa.edu

Editor's note: We received 654 responses for this medical mystery, from 61 countries. Sixty-five percent of respondents were practicing physicians, 18% were physicians in training, 10% were medical students, and 7% were other readers. Fifty-eight percent correctly diagnosed myelinated retinal nerve fibers. Other common diagnoses included

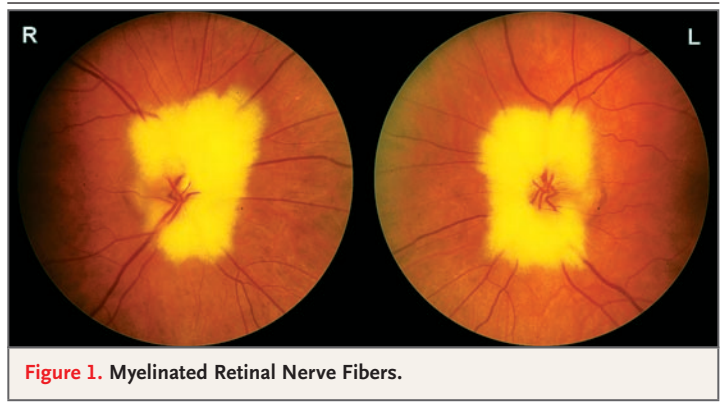


Figure 1. Myelinated Retinal Nerve Fibers.

papilledema, lipemia retinalis, glaucoma, neoplastic processes, multiple sclerosis, sarcoidosis, and a variety of infections, such as infection with cytomegalovirus, toxoplasma, or *Mycobacterium tuberculosis*. It is important not to confuse this benign finding on physical examination with optic-nerve edema.

1. Randhawa S, Lee AG. Medical mystery: cloud surrounding the optic disks. *N Engl J Med* 2008;358:69.

Review of *Thomas Eakins*

TO THE EDITOR: Greenspan's review of Amy Werbel's book, *Thomas Eakins: Art, Medicine, and Sexuality in Nineteenth-Century Philadelphia* (Oct. 25 issue),¹ contains a misstatement. In discussing the second of Eakins's "two great medical works," Greenspan refers to the subject of the painting, Dr. D. Hayes Agnew, as "a longtime professor of surgery at Jefferson Medical College." Agnew was a professor of surgery at the University of Pennsylvania and the first holder of the John Rhea Barton Professorship of Surgery. The "university amphitheater" referred to was located at the Hospital of the University of Pennsylvania.

Larry R. Kaiser, M.D.

University of Pennsylvania
Philadelphia, PA 19104
larry.kaiser@uphs.upenn.edu

1. Greenspan RE. Review of: *Thomas Eakins: Art, Medicine, and Sexuality in Nineteenth-Century Philadelphia*. *N Engl J Med* 2007;357:1782-3.

THE AUTHOR REPLIES: Kaiser has correctly pointed out that Agnew was a professor of surgery at the University of Pennsylvania Medical College and had no academic affiliation with Jefferson Medical College. Agnew had enrolled at Jefferson College in 1833, but that institution was not related to Jefferson Medical College in Philadelphia, which later became Washington and Jefferson College.

I apologize to Kaiser and to the University of Pennsylvania, and I hope that my misstatement regarding Agnew's hospital affiliation does not detract from my favorable review of Werbel's book.

Robert E. Greenspan, M.D.

7922 Washington Ave.
Alexandria, VA 22308
bobgreenspan2000@aol.com