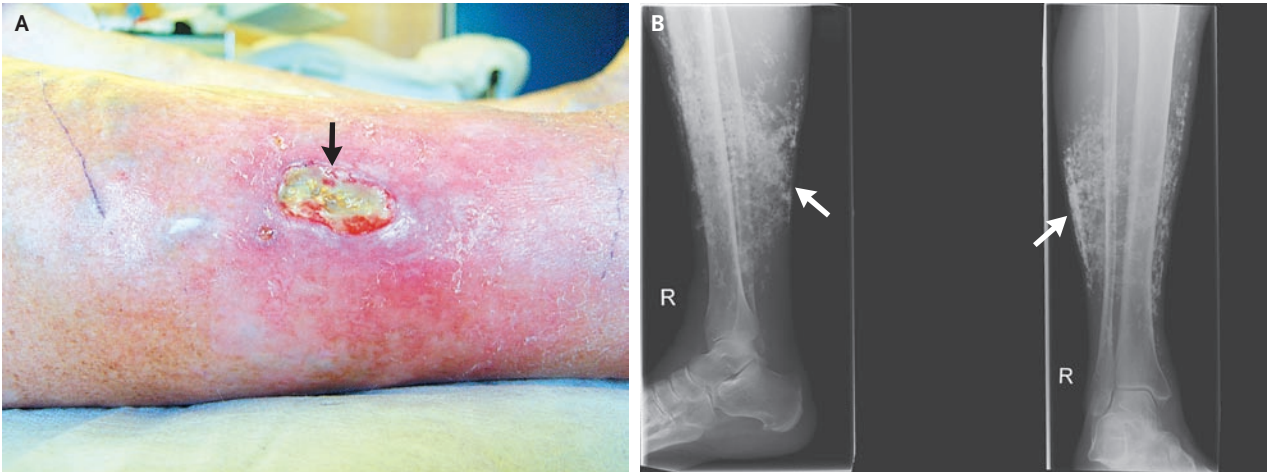


## IMAGES IN CLINICAL MEDICINE

## Chronic Venous Insufficiency and Dystrophic Subcutaneous Calcification



David Miedinger, M.D.  
Thomas Daikeler, M.D.

University Hospital  
4031 Basel, Switzerland  
miedingerd@uhbs.ch

**A** 70-YEAR-OLD WOMAN WAS REFERRED BY HER GENERAL PRACTITIONER for evaluation of an ulcerative lesion on her lower right leg. Subcutaneous white calcifications were seen (Panel A, arrow). She had worn compression stockings for several years because of bilateral recurrent ulcers caused by venous stasis. Chronic venous insufficiency was seen on duplex ultrasonography. The patient had no other associated illnesses and had normal levels of C-reactive protein, parathyroid hormone, calcium, phosphorus, serum creatinine, and 25-hydroxycholecalciferol. Chronic venous insufficiency may be accompanied by subcutaneous calcifications. These calcifications are often discovered by chance on plain radiographs (Panel B, arrows) or on ultrasonographic examination of the soft tissues and must be distinguished from calcification of the arterial or venous walls and phleboliths. The patient underwent venous stripping, curettage of the ulcer, and compression therapy; she was subsequently lost to follow-up.

Copyright © 2008 Massachusetts Medical Society.