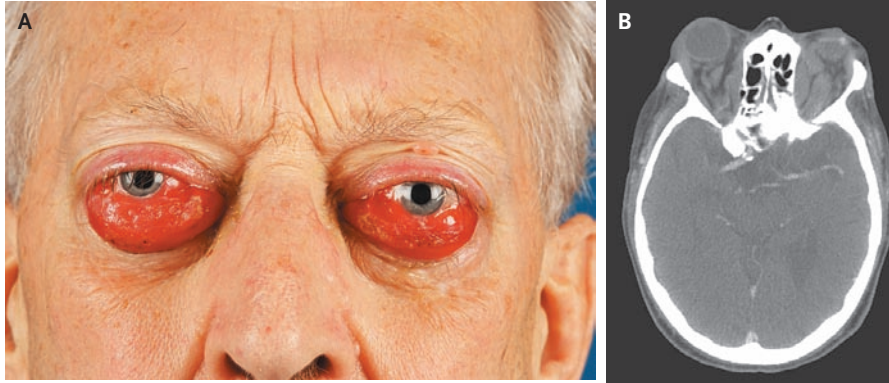


IMAGES IN CLINICAL MEDICINE

## Binocular Proptosis in Orbital Lymphoma



**A**N 81-YEAR-OLD MAN PRESENTED WITH A 7-MONTH HISTORY OF GRADUAL, painless swelling and redness of both eyes. He reported blurred vision and weight loss of 10 kg (22 lb). The physical examination revealed binocular proptosis with conjunctival injection, chemosis, and signs of exposure conjunctivitis (Panel A), along with multiple enlarged cervical and inguinal lymph nodes. Computed tomography of the head showed orbital masses that followed the contour of the orbit and did not cause bony erosion (Panel B). Pathological analysis of an inguinal lymph node showed mantle-cell lymphoma. A sample obtained on bone marrow biopsy also showed infiltration by lymphoma. The patient was treated with combination chemotherapy, and after 1 month of treatment, both the proptosis and lymphadenopathy had resolved. Five months after treatment, he had no visible or palpable signs of disease.

Copyright © 2008 Massachusetts Medical Society.

Hielke J. Meulenbeld, M.D.  
Wim Peters, M.D., Ph.D.

Catharina-Ziekenhuis Eindhoven  
5623 Eindhoven, the Netherlands