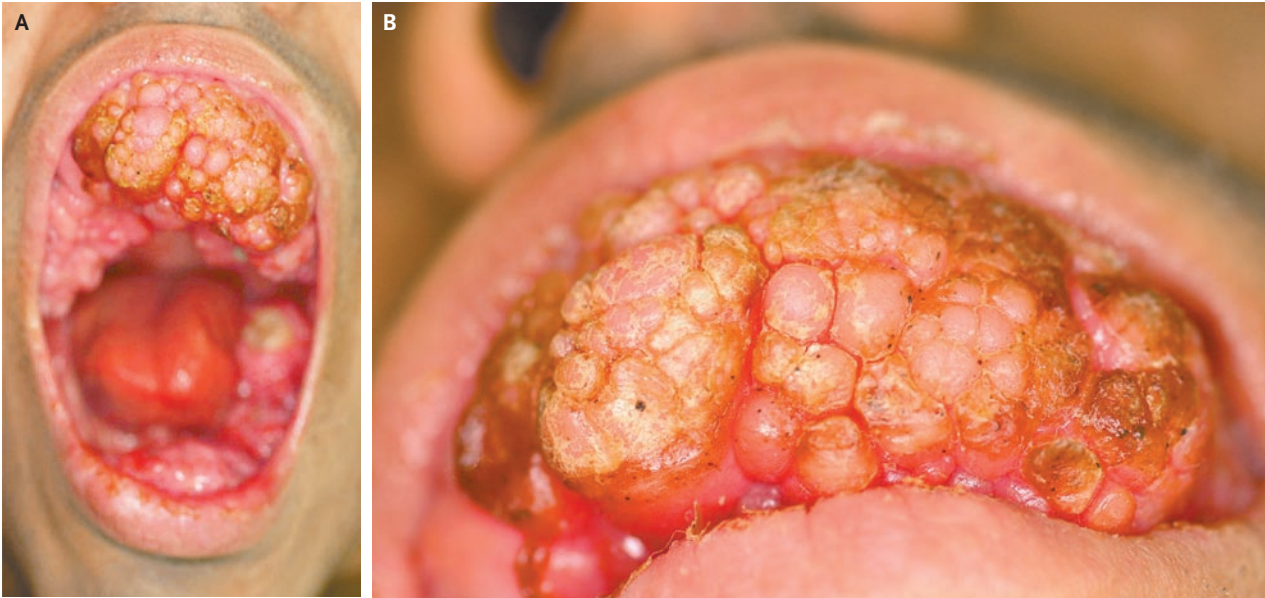


## IMAGES IN CLINICAL MEDICINE

## Medication-Induced Gingival Hypertrophy



Dong-Soo Yu, M.D.  
Young-Bok Lee, M.D.

Uijeongbu St. Mary's Hospital  
Uijeongbu, Korea  
lyb80@catholic.ac.kr

A 30-YEAR-OLD MAN PRESENTED WITH MULTIPLE ASYMPTOMATIC, FIRM, polypoid, erythematous nodules on the upper and lower gingivae, which had developed during the previous 10 years. The patient had spastic quadriplegia and mental retardation, as well as epilepsy, for which he had been taking phenytoin for more than 20 years. He had been restricted to a diet of liquids and pureed foods for several years. The physical examination revealed severe gingival hypertrophy, which obscured the patient's few remaining teeth except for the left inferior second molar (Panels A and B). Examination of a mucosal-biopsy specimen showed proliferation of fibroblasts and an increased number of collagen fibers, as well as glycosaminoglycans. With time, such gingival overgrowth may develop in patients taking phenytoin, a condition that may be exacerbated by poor oral hygiene. Severe overgrowth may lead to impairment in gingival function, requiring surgical excision of the excessive tissue. In the case of this patient, treatment of the gingival overgrowth was declined.

Copyright © 2009 Massachusetts Medical Society.