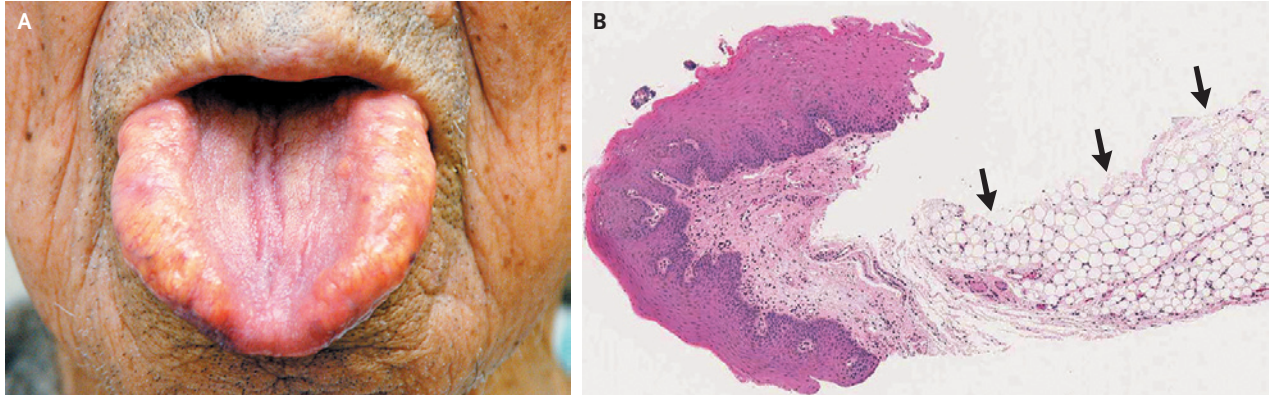


IMAGES IN CLINICAL MEDICINE

Lipomatosis of the Tongue



AN 88-YEAR-OLD MAN PRESENTED WITH DIFFUSE, PAINLESS SWELLING OF the lateral borders of his tongue (Panel A). The swelling had been slowly increasing during the previous 20 years. Yellowish tumors with a smooth, shiny surface were visible. There was no frank macroglossia, dysphagia, dysarthria, or sleep apnea. No other tumors were identified anywhere in the body, including the oral cavity and the gastrointestinal tract, which were evaluated endoscopically. There was no cervical lymphadenopathy. Serum glucose and lipid levels were normal. The patient had no atherosclerotic disease, he did not drink alcohol, and no family members were similarly affected. Examination of a specimen from an incisional biopsy showed lobules of mature adipose tissue that were consistent with lipomatosis (Panel B, arrows); there was no evidence of liposarcoma. He received no treatment. Lipomas are very common; however, isolated lipomatosis of the tongue is rare.

Copyright © 2009 Massachusetts Medical Society.

Hiroshi Murakami, M.D.
Naoki Tamasawa, M.D.
Hirosaki University Graduate School
of Medicine
Hirosaki 036-8562, Japan