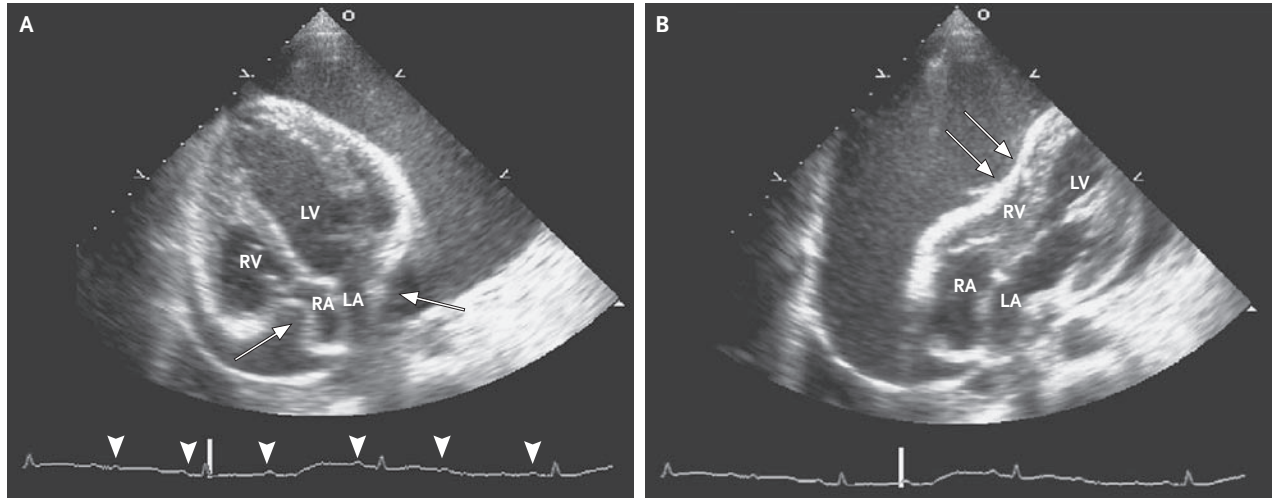


IMAGES IN CLINICAL MEDICINE

A Swinging Heart



A 39-YEAR-OLD WOMAN WITH A 1-YEAR HISTORY OF STAGE IV MELANOMA presented with progressive shortness of breath, fatigue, and edema in the legs, which had developed over the course of the previous week. At the time of the melanoma diagnosis, a mediastinal and right supraclavicular mass had been seen without identification of a primary tumor. The patient had been treated with five cycles of biochemotherapy and then with antibodies against cytotoxic T lymphocyte antigen 4. Subsequently, the superior vena cava syndrome and tracheal compression had developed, which had required stenting. The patient had then received radiation therapy. Integrated positron-emission tomography and computed tomography continued to show active and spreading disease. The physical examination revealed hypotension, tachycardia, jugular venous distention, pulsus paradoxus, and distant heart sounds. The blood pressure was 82/64 mm Hg, and the heart rate was 110 beats per minute. Transthoracic echocardiography showed a large pericardial effusion with swinging of the heart (video) and collapse of the right atrium (RA) and left atrium (LA) in end diastole (Panel A, arrows) and diastolic collapse of the right ventricle (RV) (Panel B, arrows), which was consistent with pericardial tamponade. Pericardiocentesis yielded 1.6 liters of bloody fluid; the fluid was subsequently shown to be a malignant effusion. Swinging of the heart that is due to a large pericardial effusion is responsible for the beat-to-beat shift in the axis, amplitude, and morphology of the QRS interval (electrical alternans) on electrocardiography. In this patient, the condition resulted in a “pseudo” 2:1 atrioventricular-block pattern, with an absent QRS interval after every other P wave (Panel A, arrowheads), despite ventricular contraction on echocardiography. Follow-up echocardiography over the next 2 days showed no reaccumulation of effusion. Paclitaxel was administered, but the patient died within 2 months after the initiation of therapy.

Copyright © 2009 Massachusetts Medical Society.

John R. Kapoor, M.D., Ph.D.
Michael V. McConnell, M.D.

Stanford University
Stanford, CA