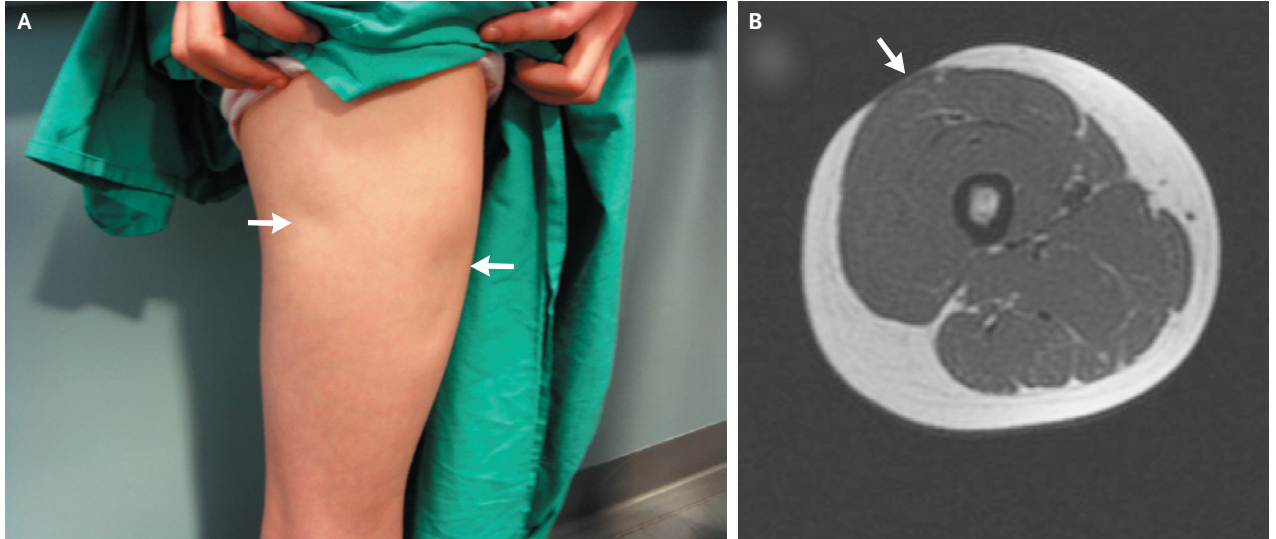


## IMAGES IN CLINICAL MEDICINE

## Injection-Site Lipoatrophy



A 13-YEAR-OLD GIRL WITH A 20-MONTH HISTORY OF TYPE 1 DIABETES MELLITUS presented with depressed areas of skin at the sites of insulin injection (Panel A, arrows). The patient had been treated since diagnosis with injections of biphasic insulin lispro (Humalog Mix 25, Eli Lilly) into both thighs. The physical examination and axial magnetic resonance imaging of the right thigh showed a loss of the adipose tissue layer at the injection sites. One injection site is shown in Panel B (arrow). Injection-site lipoatrophy is a recognized complication that is associated with all types of insulin and that has an estimated prevalence of 3.6%. The condition can be unsightly clinically and theoretically could lead to erratic insulin absorption. The precise pathogenesis remains unclear, but possible mechanisms include immune reaction to insulin or excipients of the injection solution, injury from cold insulin, or trauma from repeated local injections. After the discovery of lipoatrophy, the patient discontinued injecting insulin into the right thigh, and the areas of depression gradually diminished over a 10-month period.

Copyright © 2009 Massachusetts Medical Society.

Adziri Harold Sackey, F.R.C.P.C.H.

Mid Cheshire Health Foundation Trust  
Cheshire, United Kingdom  
sackey@sky.com